

Interesting coincidence of liver abscess secondary to foreign body and gastric inflammatory fibroid polyp

Catherine Behzad^{1*} , Mohammad Reza Hasanjani Roushan² , Abolhasan Alijanpour¹ , Hossein Ghorbani¹ , Hossein Shahabandaz¹ 

¹Clinical Research Development Unit, Rouhani University Hospital, Babol University of Medical Sciences, Babol, Iran

²Infectious Diseases and Tropical Medicine Research Center, Health Research Institute, Babol University of Medical Sciences, Babol, Iran

Cite this article as: Behzad C, Hasanjani Roushan MR, Alijanpour A, Ghorbani H, Shahabandaz H. Interesting coincidence of liver abscess secondary to foreign body and gastric inflammatory fibroid polyp. *Turk J Gastroenterol* 2020; 31(9): 673-5.

Dear Editor,

Ingestion of foreign body is common and more than 80% of ingested foreign bodies pass without the need for intervention. Obstruction and perforation of the alimentary tract are the most common complications (1). However, ingested foreign bodies may have different unexpected consequences.

A 59-year-old woman was admitted for abdominal pain, fever, and chills. Her past medical history was remarkable for laminectomy being performed twice.

On the date of admission, she had the blood pressure of 100/60mmHg, the respiratory rate of 18 times/min, the heart rate of 88 beats/min, and the body temperature of 39.6°C. Physical examination was normal except for mild epigastric tenderness.

Laboratory investigation showed marked inflammation—erythrocyte sedimentation rate: 120mm/h, C-reactive protein concentration: 92 mg/dL, white blood count:15,800/m³ (neutrophil 77%, lymphocyte 19%, and monocytes 2%), hemoglobin:9.1 g/dL, platelet count: 369,000/m³, total iron binding capacity:170 mcg/dL,iron (Fe):15mcg/dL, and ferritin:176 ng/mL.

Liver function tests, serum creatinine level, and blood and urine cultures in addition to chest radiograms did not show any abnormality.

Abdominal ultrasonography showed a septated cystic mass lesion in the liver.A contrast enhanced abdominal computed tomography scan showed a heterogeneous multiloculated hypodense cystic mass lesion in the hepatic left lower lobe, measuring 82×74×118 mm,mostly suggestive of abscess or hydatid cyst (Figure 1). Serologic

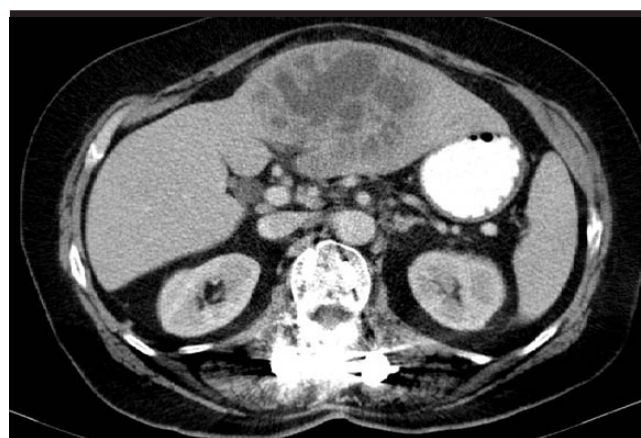

Figure 1. Abdominal CT showing heterogenous multiloculated hypodense mass 206x162 mm.

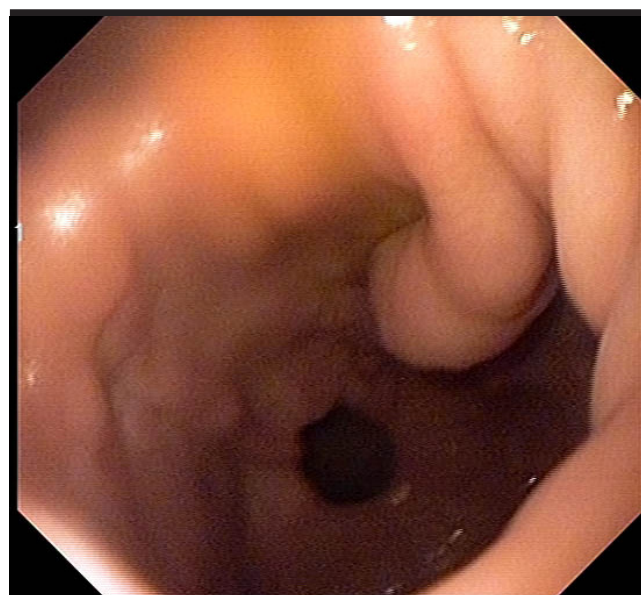


Figure 2. Endoscopic view of gastric polyp.

Corresponding Author: Catherine Behzad; catherinebehzad@yahoo.com

Received: April 16, 2019 Accepted: August 18, 2019

© Copyright 2020 by The Turkish Society of Gastroenterology · Available online at turkjgastroenterol.org

DOI: 10.5152/tjg.2020.19284

tests for hydatid disease did not show any abnormality. Because of the probability of gastrointestinal malignancy in relation with hepatic lesion and anemia with iron deficiency, colonoscopy and endoscopy were performed. Colonoscopy was unremarkable, but a 20-mm polyp with a smooth surface was revealed in the posterior wall of the stomach in upper endoscopy (Figure 2); diagnosis of inflammatory fibroid polyp was made following pathologic evaluation of biopsy samples (Figures 3 and 4). After discussion about the case, abscess drainage through open laparotomy was planned. Following laparotomy an abscess was seen in the left liver lobe, which was drained; further evaluation of the abscess cavity revealed a toothpick-like wood that was extracted (Figures 5 and 6); a surgical drain was inserted and left in place four days until drainage was almost stopped. Meropenem in a dosage of

1 g tid was administered for one week after the surgery, and the patient was discharged ten days after the surgery in good condition, afebrile, and symptom free.

Here, we report a case of rare cause of liver abscess accompanying a rare-type polyp in the stomach.

Pyogenic liver abscesses are the most common type of visceral abscess (2). However, liver abscesses secondary to foreign bodies, which penetrates the gastrointestinal tract, are very rare, and few cases have been reported in the medical literature(3). Although the area of penetration cannot be proved in most cases, localization of perforation in very few cases has been observed in the stomach or duodenum (3). Foreign body's migration is usually silent for a long time and is discovered only if there is infection or abscess (3, 6).

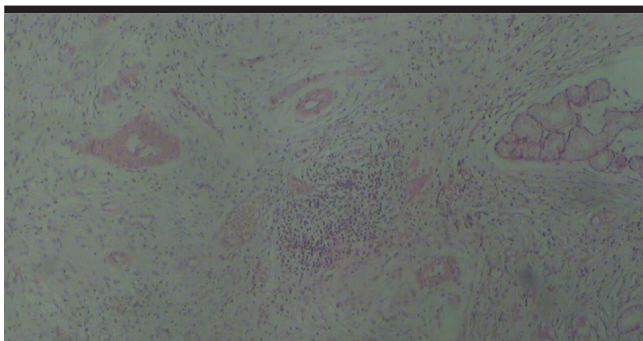


Figure 3. Biopsy of Antral Polyp. Hematoxylin & eosin Stain.

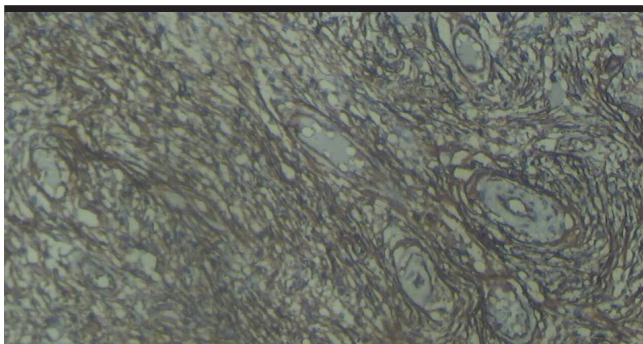


Figure 4. Biopsy of Antral Polyp. IHC Stain.

MAIN POINTS

- Foreign body should be considered as a probable etiology of liver abscess.
- Many of the patients do not remember foreign body ingestion.
- Foreign body and inflammation in stomach may cause inflammatory fibroid polyp.

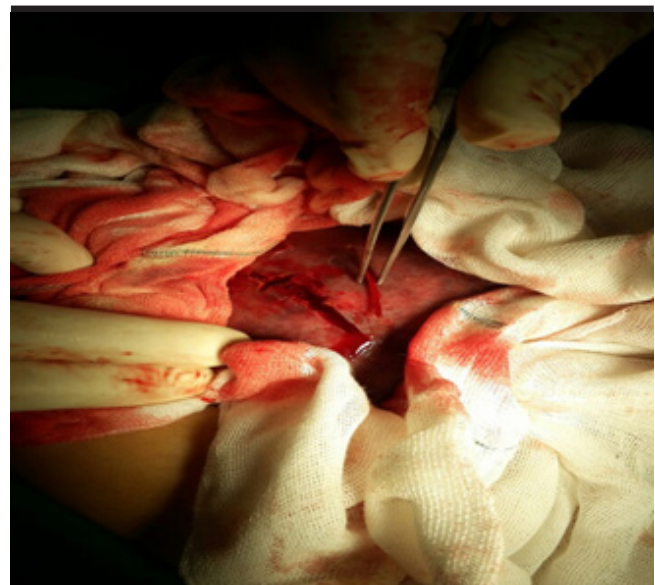


Figure 5. Extracted toothpick from abscess cavity by surgery.

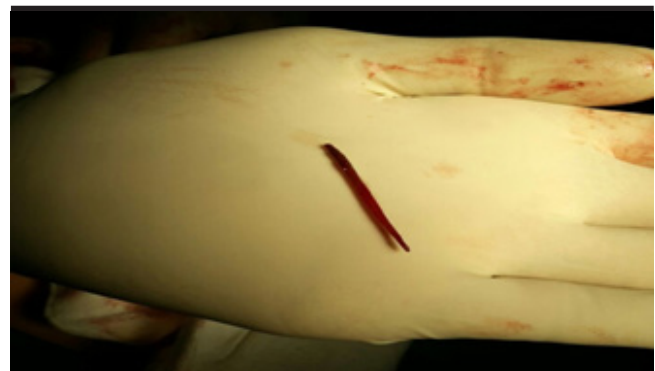

Figure 6. Liver foreign body.

The other finding in our patient was a gastric inflammatory fibroid polyp in the stomach antrum.

This type of polyp is extremely rare and accounts for 0.1% of gastric polyps (4). These lesions are benign mesenchymal tumors (4). Their etiology is not exactly known, but association with the inflammatory process, foreign body, parasite larva, infection, and pernicious anemia has been reported (4, 5).

Endoscopic evaluation of our patient showed that the base of the polyp was located on the posterior wall of the gastric antrum in the lesser curvature, which is anatomically adjacent and in front of the left liver lobe; considering all issues, we suppose that in this patient, the wood perforated the gastric wall and penetrated to the left lobe of the liver. Formation of an inflammatory fibroid polyp was probably a result of inflammation caused by foreign body and perforation in the stomach.

To the best of our knowledge, this is the first case with coincidence of liver abscess and gastric inflammatory fibroid polyp, both as a consequence of ingested foreign body.

Our patient did not have any history of foreign body ingestion; she presented with fever and abdominal pain, so it was not possible to establish the time of ingestion of the toothpick-like wood. Perforation of the gastric wall and foreign body migration toward the liver remained silent until abscess formation. Although a computed tomography scan showed liver abscess, foreign body could not be distinguished in imaging, and the final diagnosis was only established by surgery. Other similar case presentations have been reported by others (4, 6).

In conclusion, foreign body should be considered as a probable etiology in any patient with liver abscess. Di-

agnosis may be difficult as most of the patients do not remember foreign body ingestion, and typical symptoms are absent in some cases (4).

Informed Consent: Informed consent was obtained from the patient who participated in this study.

Peer-review: Externally peer-reviewed.

Author contributions: Concept – C.B., M.R.H.R.; Design – C.B., M.R.H.R.; Supervision – C.B., M.R.H.R.; Resource – C.B., M.R.H.R.; Materials – C.B., M.R.H.R., A.A., H.G., H.S.; Data Collection and/or Processing – C.B., M.R.H.R., A.A., H.G., H.S.; Analysis and/or Interpretation – C.B., M.R.H.R., A.A., H.G., H.S.; Literature Search – C.B., M.R.H.R.; Writing – C.B., M.R.H.R.; Critical Reviews – C.B., M.R.H.R., A.A., H.G., H.S.

Acknowledgements: The authors thank all the staff of infectious disease ward.

Conflict of Interest: The authors have no conflict of interest to declare.

Financial Disclosure: The authors declare that this study has received no financial support.

REFERENCES

1. McCanse DE, Kurchin A, Hinshaw JR. Gastrointestinal foreign bodies. *Am J Surg* 1981; 142: 335-7. [\[Crossref\]](#)
2. Rahimian J, Wilson T, Oram V, Holzman RS. Pyogenic liver abscess: recent trends in etiology and mortality. *Clin Infect Dis* 2004; 39: 1654-9. [\[Crossref\]](#)
3. Chong LW, Sun CK, Wu CC, Sun CK. Successful treatment of liver abscess secondary to foreign body penetration of the alimentary tract: A case report and literature review. *World J Gastroenterol* 2014; 20: 3703-11. [\[Crossref\]](#)
4. Rossi P, Montuori M, Balassone V, et al. Inflammatory fibroid polyp. A case report and review of the literature. *Ann Ital Chir* 2012; 83: 347-51.
5. Calderon MG, Caivano VC, Bagnaresi S, et al. A unique case of inflammatory fibroid polyp in duodenum of a female adolescent: case report and literature review.
6. Matrella F, Lhuire M, Piardi T, et al. Liver hilar abscesses secondary to gastrointestinal perforation by ingested fish bones: surgical management of two cases. *Hepatobiliary Surg Nutr* 2014; 3: 156-62.