

## How should trichobezoar be treated in children?

Fulya Gülerman<sup>1</sup> , Burcu Güven<sup>1</sup> , Sabri Demir<sup>2</sup> , İsmail Özmen<sup>2</sup>

<sup>1</sup>Department of Pediatric Gastroenterology, Kırıkkale University School of Medicine, Kırıkkale, Turkey

<sup>2</sup>Department of Pediatric Surgery, Kırıkkale University School of Medicine, Kırıkkale, Turkey

**Cite this article as:** Gülerman F, Güven B, Demir S, Özmen İ. How should trichobezoar be treated in children? *Turk J Gastroenterol* 2019; 30(7): 660-1.

Dear Editor,

Bezoars are accumulated collections of indigestible material in the gastrointestinal tract. Although their true incidence in the pediatric population is unknown, bezoars usually occur in females, adolescents, and children with psychiatric or neurological disorders (1).

The treatment changes according to the type of bezoar and its location. It can be conservative or surgical. Recently, the effectiveness of Coca-Cola for the dissolution of gastric bezoar has been reported (2).

Here, we present a case of gastric trichobezoar treated by endoscopic fragmentation in combination with Coca-Cola administration.

A 13-year-old-girl presented to the gastroenterology clinic due to abdominal fullness and discomfort. Physical examination revealed a palpable tumor sized 10×7 cm within the epigastrium. On barium abdominal X-ray and computed tomography, the stomach was found to be distended and filled with a large solid mass (Figure 1). The patient had a habit of eating hair, light rope, nails, and wet wipes.

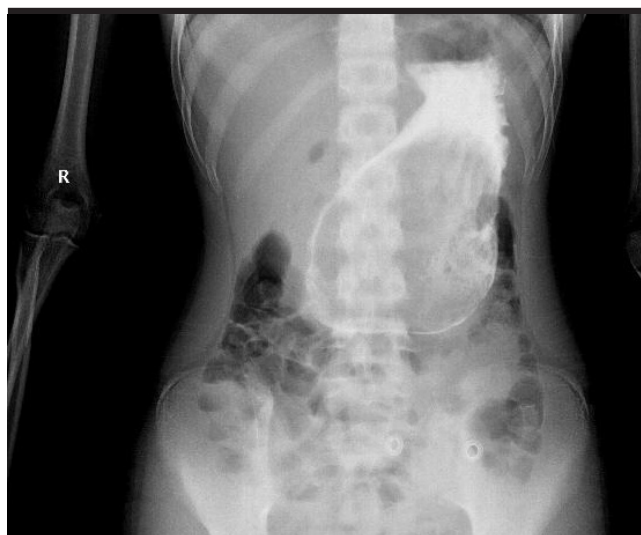Upper gastrointestinal endoscopy was performed. The inner cavity of the stomach was filled with a large bezoar composed of hair and light ropes (Figure 2). We injected Coca-Cola into the bezoar from multiple directions. Attempts of endoscopic fragmentation using mouse-teeth clamp and polypectomy snare were unsuccessful because of hard consistency of the bezoar. After endoscopy, we administered oral Coca-Cola, adjuvant prokinetics, and pancreatic enzyme supplements.

At the end of second week, the gastric bezoar had dissolved partially. Coca-Cola was injected through the ac-

cessory working channel into the bezoar mass, and the mass was fragmented using several accessories. Medical therapy was continued.

At the end of third week, the size of the bezoar increased and compacted. After endoscopy, it was learned that the patient continued to eat hair. A giant bezoar sized 15×11 cm was resected during surgery.

In 2013, Ladas et al. (3) published a review of adult cases with Coca-Cola administration and reported complete phytobezoar dissolution in 50% of cases and partial dissolution and concomitant endoscopic removal in additional 41.3% cases. Lee et al. (4) reported that complete dissolution of bezoars was observed in 23.5% of cases, whereas partial dissolution was observed in 76.5% cases treated with Coca-Cola administration. It is interesting to note that Coca-Cola is completely ineffective for persim-



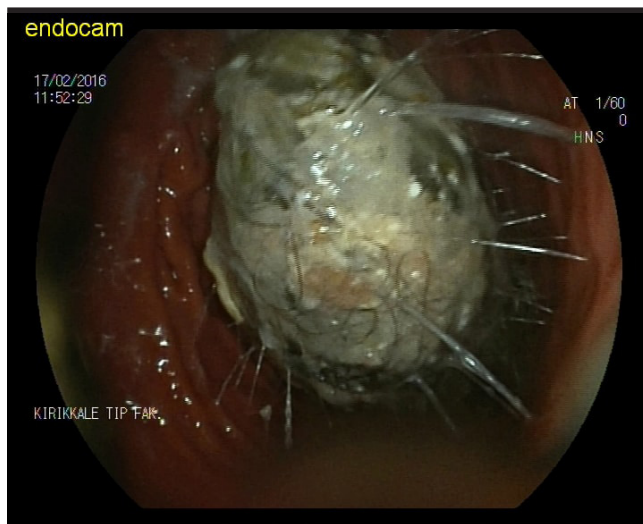
**Figure 1.** On barium abdominal X-ray and computed tomography, the stomach was found to be distended and filled with a large solid mass

Corresponding Author: Fulya Gülerman; [fulyagulerman@gmail.com](mailto:fulyagulerman@gmail.com)

Received: May 25, 2018 Accepted: September 17, 2018 Available online date: November 28, 2018

© Copyright 2018 by The Turkish Society of Gastroenterology · Available online at [www.turkjgastroenterol.org](http://www.turkjgastroenterol.org)

DOI: 10.5152/tjg.2018.18423



**Figure 2.** The inner cavity of the stomach was filled with a large bezoar composed of hair and light ropes

mon phytobezoars (4). Because of different risk factors and etiologies, these data may not generalizable to the pediatric population.

In the literature, a few interesting cases, including some of children, were treated effectively with Coca-Cola administration, with direct injection of small amounts of Coca-Cola directly into the bezoar. However, all of them were phytobezoar (1,4). There has been no report on trichobezoar treated with Coca-Cola administration. We treated a trichobezoar by endoscopic fragmentation in combination with Coca-Cola administration. At second week, we were partially successful. However, due to continued hair eating and persistence of the bezoar, we had to opt for surgical resection.

In conclusion, Coca-Cola administration may be inexpensive, effective, safe, and well-tolerated first-line alternative to surgical or endoscopic removal of bezoars. However, it is not as effective in treating trichobezoar as in case of phytobezoar.

**Informed Consent:** Written informed consent was obtained from the patient's parents who participated in this study.

**Peer-review:** Externally peer-reviewed.

**Author Contributions:** Concept - F.G., B.G.; Design - S.D.; Supervision - S.D., İ.Ö.; Resource - S.D., İ.Ö.; Materials - B.G.; Data Collection and/or Processing - F.G., B.G.; Analysis and/or Interpretation - F.G., B.G.; Literature Search - B.G.; Writing Manuscript - F.G., B.G.; Critical Reviews - İ.Ö., S.D.

**Conflict of Interest:** The authors have no conflict of interest to declare.

**Financial Disclosure:** The authors declared that this study has received no financial support.

## REFERENCES

1. Azevedo S, Lopes J, Marques A, Mourato P, Freitas L, Lopes AI. Successful endoscopic resolution of a large gastric bezoar in a child. *World J Gastrointest Endosc* 2011; 3: 129-32. [\[CrossRef\]](#)
2. J Lin CS, Tung CF, Peng YC, Chow WK, Chang CS, Hu WH. Successful treatment with a combination of endoscopic injection and irrigation with coca cola for gastric bezoar-induced gastric outlet obstruction. *Chin Med Assoc* 2008; 71: 49-52. [\[CrossRef\]](#)
3. Ladas SD, Kamberoglou D, Karamanolis G, Vlachogiannakos J, Zouboulis-Vafiadis. Systematic review: Coca-Cola can effectively dissolve gastric phytobezoars as a first-line treatment. *Aliment Pharmacol Ther* 2013; 37: 169-73. [\[CrossRef\]](#)
4. Lee BJ, Park JJ, Chun HJ, et al. How good is cola for dissolution of gastric phytobezoars? *World J Gastroenterol* 2009; 15: 2265-9. [\[CrossRef\]](#)