



The gastric outlet herniated through the hiatus with the normal gastroesophageal junction and fundus

Xiaoli Zhan, Yuedong Wang

Department of General Surgery, Second Affiliated Hospital Zhejiang University College of Medicine, Hangzhou, China

To the Editor,

A 67-year-old man presented with a 16-months history of nausea, bloating, postprandial fullness, and multiple episodes of vomiting. A contrast-enhanced CT scan and an upper GI contrast study were performed in another hospital approximately 9 months earlier (Figure 1a-c). On presentation, his vital signs were stable. A physical examination revealed a distended upper abdomen with light tenderness but no rebounding pain. Chest X-ray imaging was then performed (Figure 1d).

The patient underwent laparoscopic surgery. An initial laparoscopic inspection revealed that the distal stomach and proximal duodenum herniated in the hiatus, that the gastroesophageal junction (GEJ) and fundus remained in their normal intraabdominal position, and that the stomach was severely distended (Figure 2a, b).

Crura were identified, and an incision was made the anterior arch of the hiatus. The hernia sac was anteriorly grasped and dissected from the mediastinum. With gentle and persistent retraction of the stomach and duodenum, the incarcerated distal stomach and duodenum were reduced from the mediastinum and returned to the abdomen (Figure 2c). Posterior cruroplasty with mesh reinforcement was then performed (Figure 2d).

Hiatal hernia is characterized by the protrusion of an abdominal structure other than the esophagus into the thoracic cavity through the widening of the hiatus of the diaphragm.(1) More than 95% of hiatal hernias are type I (small sliding hernias), where the GEJ migrates above the diaphragm(1). Paraesophageal hernias represent a subtype (types II to IV) of this disease and account for 5% of all hiatal hernias (1,2). In type II hernias,

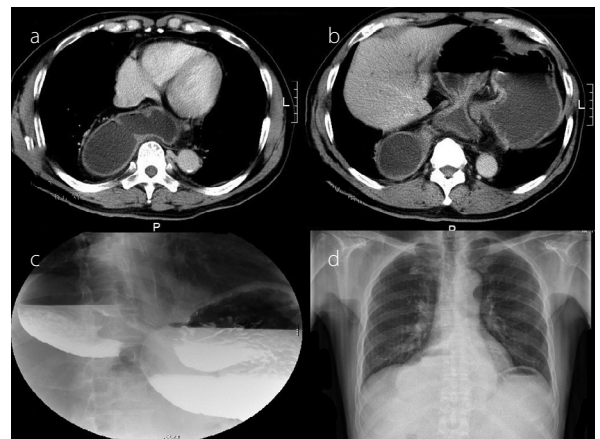

Figure 1. a-d. (a, b) A CT scan showing that the distal stomach and proximal duodenum herniated through the hiatus and well into the left chest and that the gastroesophageal junction (GEJ) and fundus remained in the abdomen. (c) An upper GI study showing the distal stomach and proximal duodenum with an air-fluid level located in the chest, and the GEJ and fundus with another air-fluid level remained in the abdomen. (d) A chest X-ray image showing a soft tissue opacity with an air-fluid level located in the right chest, and the fundus with another air-fluid level remained in the abdomen

a portion of the fundus herniates through the hiatus adjacent to the esophagus, while the GEJ remains in its normal position (1,3). When the GEJ and fundus herniate through the hiatus, it is a type III hernia (1,3). When the hiatal defect is very large, thereby allowing herniation of the entire stomach or other viscera such as the colon and spleen, it is termed as type IV hiatal hernia (3).

In our case, the gastric outlet herniated through the hiatus with the normal position of the GEJ and fundus. It is consistent with the above definition of hiatal hernia, but we cannot refer to it as either type based on the current anatomic classification. It is definitely not type I hiatal hernia; it is also not type II hiatal hernia because of the normal position of the fundus. It is also not type

Address for Correspondence: Yuedong Wang E-mail: wydong2003@hotmail.com

Received: December 21, 2016 **Accepted:** December 25, 2016 **Available Online Date:** January 26, 2017

© Copyright 2017 by The Turkish Society of Gastroenterology • Available online at www.turkjgastroenterol.org • DOI: 10.5152/tjg.2017.16731

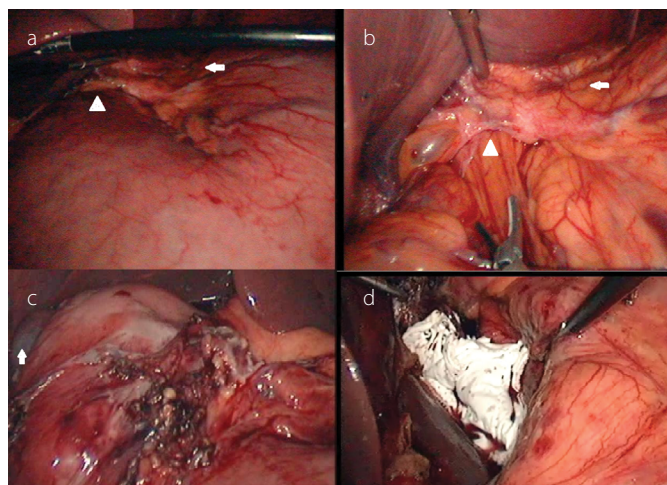


Figure 2. a-d. (a) A laparoscopic image showing that the stomach distended severely (arrow: cardia; arrowhead: incarcerated distal stomach in the hiatus). (b) A laparoscopic image (arrow: cardia; arrowhead: incarcerated distal stomach in the hiatus). (c) A laparoscopic image showing the reduced first portion of the duodenum and the antrum (arrow: gallbladder). (d) A laparoscopic image showing reinforced hiatal repair with a mesh

III hernia because of normal position of the GEJ. Therefore, the above subtype definition of hiatal hernias does not suit it; it is an unusual retrograde hiatal hernia. We could not find any similar report in the literature.

Ethics Committee Approval: Ethics committee approval was received for this study from the ethics committee of the Second Affiliated Hospital Zhejiang University College of Medicine.

Informed Consent: Written informed consent was obtained from the patient who participated in this study.

Peer-review: Externally peer-reviewed.

Author Contributions: Concept - Y.W., X.Z.; Literature Review - X.Z.; Writer - X.Z., Y.W.; Critical Review - Y.W.

Conflict of Interest: No conflict of interest was declared by the authors.

Financial Disclosure: The authors declared that this study has received no financial support.

REFERENCES

1. Kohn GP, Price RR, DeMeester SR, et al. Guidelines for the management of hiatal hernia. *Surg Endosc* 2013; 27: 4409-28. [\[CrossRef\]](#)
2. Mungo B, Molena D, Stem M, Feinberg RL, Lidor AO. Thirty-Day Outcomes of Paraesophageal Hernia Repair Using the NSQIP Database: Should Laparoscopy Be the Standard of Care? *J Am Coll Surg* 2014; 219: 229-36. [\[CrossRef\]](#)
3. Schauer PR, Ikramuddin S, McLaughlin RH, et al. Comparison of laparoscopic versus open repair of paraesophageal hernia. *Am J Surg* 1998; 176: 659-65. [\[CrossRef\]](#)