



## Primary mesenchymal tumors of the colon: A report of three cases

Arzu Yaren<sup>1</sup>, Serkan Değirmencioğlu<sup>1</sup>, Neşe Çallı Demirkan<sup>2</sup>, Atike Gökçen Demiray<sup>1</sup>, Burcu Taşköylü<sup>1</sup>, Gamze Gököz Doğu<sup>1</sup>

<sup>1</sup>Department of Medical Oncology, Pamukkale University Faculty of Medicine, Denizli, Turkey

<sup>2</sup>Department of Pathology, Pamukkale University Faculty of Medicine, Denizli, Turkey

### ABSTRACT

Primary mesenchymal tumors of the colon are extremely rare tumors among soft tissue sarcomas. These tumors are more aggressive and have poorer prognosis than adenocarcinoma of the colon. Here, we presented 3 cases of primary mesenchymal tumors of the colon. Their histopathological diagnoses are leiomyosarcoma, pleomorphic liposarcoma, and desmoplastic small round cell tumor, respectively. The rarity of primary mesenchymal tumors of the colon makes it difficult to approach the treatment and predict the prognosis of these rare tumors.

**Keywords:** Colon, desmoplastic small round cell tumor, leiomyosarcoma, liposarcoma

### INTRODUCTION

Primary mesenchymal tumors of the gastrointestinal tract are rarely seen, representing only 0.1%-3% of all gastrointestinal cancers. The most common histopathologic type is leiomyosarcoma. Other rare types, such as liposarcoma, malignant fibrous histiocytoma, synovial sarcoma, and desmoplastic small round tumor, are presented as case reports (1). We herein reported 3 cases of primary mesenchymal tumors of the colon that are uncommonly seen and review the literature to notice these rare tumors' features, such as diagnosis, treatment, and prognosis.

### CASE PRESENTATIONS

#### Case 1

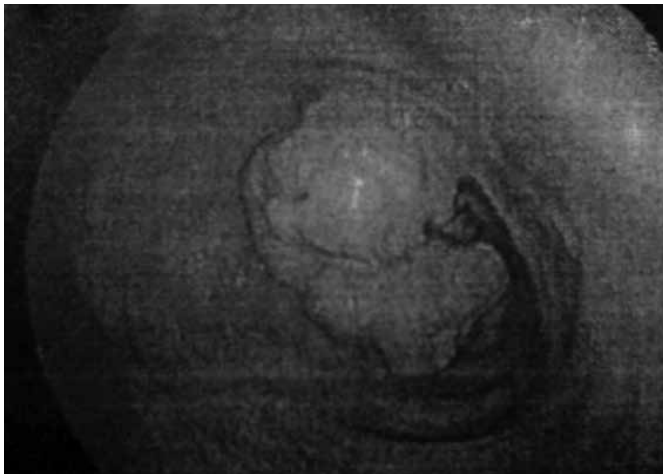
A 66-year-old woman presented complaining of abdominal pain, fever, and a history of rectal bleeding. Her past medical history and family history were unremarkable. On physical examination, a solid non-tender mass was palpable in the upper left quadrant of the abdomen. Laboratory tests on admission were obtained. She had anemia (hemoglobin value: 8.8 gr/dL), increased serum level of lactate dehydrogenase (LDH:335 IU/L; range:125-243), high C-reactive protein level (CRP:30.2

mg/dL; range: 0-0.5 mg/dL), and normal tumor markers. A colonoscopy was performed, demonstrating an intraluminal lesion in the transverse colon (Figure 1). Abdominopelvic computed tomography (CT) scans showed a 9x5.5 cm lesion located at the transverse colon, extending to the splenic flexure (Figure 2). Further examinations for distant metastases were negative. The patient underwent a right hemicolectomy. Gross examination revealed an encapsulated, gray-whitish polypoid mass 4x3x3 cm in size, obliterating the colonic lumen. Histological examination showed that the tumor was composed of interlacing and parallel fascicles of spindle cells with pleomorphic and hyperchromatic nuclei between the necrotic areas (Figure 3). Immunohistochemically, smooth muscle actin and muscle-specific actin staining were diffusely positive, whereas desmin, S-100, CD 117, and CD 34 staining was negative. More than 5 mitoses were counted in 10X high-power fields. Ki-67 labeling index was more than 90%. Pathological examination of the specimen revealed "high-grade leiomyosarcoma of the colon," and there was no lymph node involvement. After surgery, adjuvant ifosfamide plus doxorubicin chemotherapy was given because of the high grade and high proliferation index; 33 months after the chemotherapy, the patient was well without

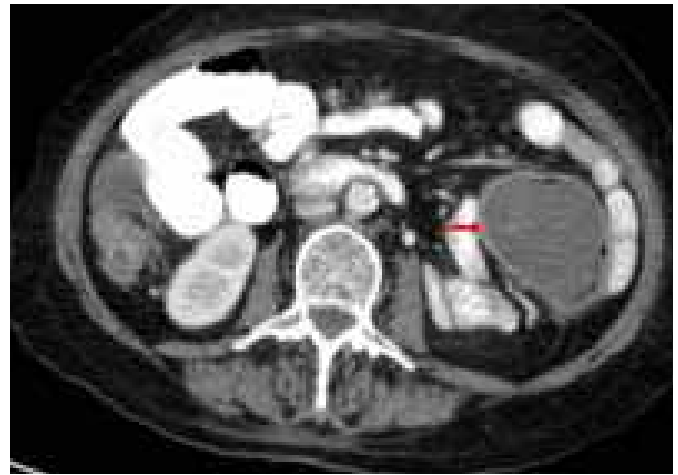
**Address for Correspondence:** Arzu Yaren, Department of Medical Oncology, Pamukkale University Faculty of Medicine, Denizli, Turkey  
E-mail: arzu\_yaren@yahoo.com

**Received:** 27.12.2012 **Accepted:** 7.12.2012

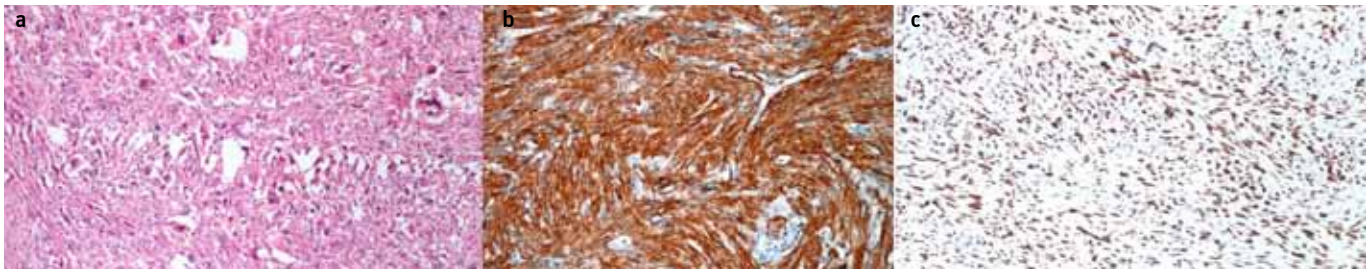
© Copyright 2014 by The Turkish Society of Gastroenterology • Available online at [www.turkjgastroenterol.org](http://www.turkjgastroenterol.org) • DOI: 10.5152/tjg.2014.4010



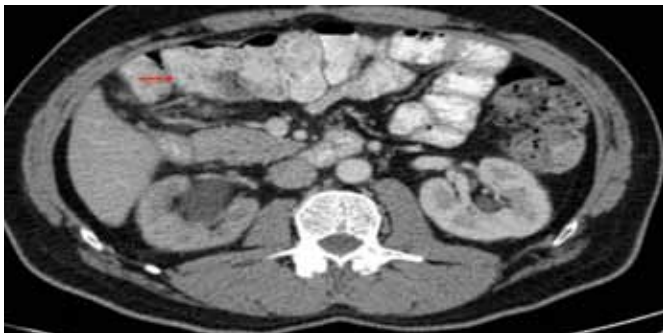**Figure 1.** A colonoscopy shows an intraluminal lesion in the transverse colon.



**Figure 2.** Abdominopelvic CT shows a 9x5.5cm lesion located at the splenic flexure.



**Figure 3. a-c.** Pathological examination shows pleomorphic spindle cell proliferation at H&E X100 magnification (a) strong expression of smooth muscle actin (b) and Ki-67 labeling index shows 90% nuclear positivity (c).



**Figure 4.** Abdominopelvic CT shows a large lesion located in the ascending colon.

evidence of disease. The written informed consent was obtained from the patient.

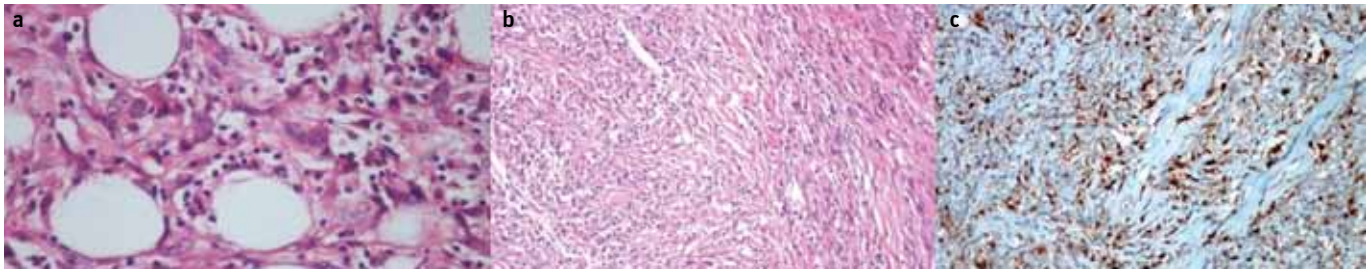
## Case 2

A 56-year-old man was admitted to the hospital suffering from abdominal pain and diarrhea. He had neither a significant past medical history nor a family history. The blood tests (cell count, blood chemistry, and tumor markers) were normal in the reference range. A total colonoscopy demonstrated a polyp at the ascending colon, and abdominopelvic CT revealed an approximately 7-cm-sized enhancing solid mass, located in the ascending colon (Figure 4). He underwent extended right hemicolectomy. Further examinations were negative for metastatic disease. Macroscopic examination revealed a gray-yellowish solid mass, measuring 9x4x4 cm. In the microscopic examina-

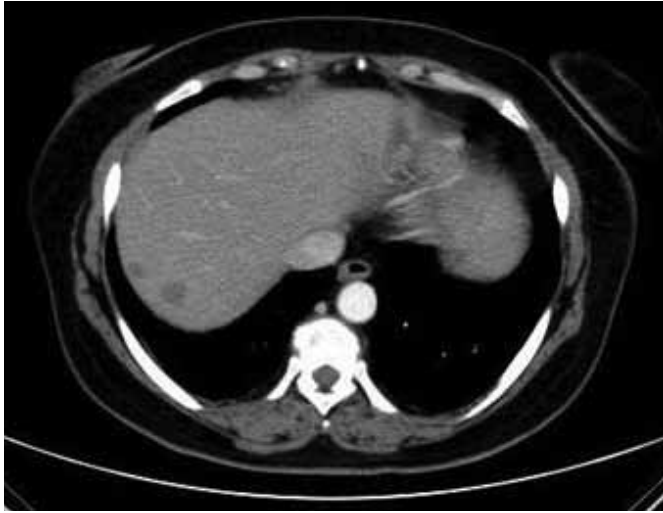tion, there was a proliferation of pleomorphic spindle-shaped lipoblasts with atypical, multivaculated, and hyperchromatic nuclei. Four mitoses were counted in the 10X high-power field. Immunohistochemically, S-100 was diffusely positive and smooth muscle actin (SMA), muscle-specific actin, desmin, glial fibrillary acidic protein (GFAP), CD 117, and CD 34 staining was negative. Ki-67 labeling index was more than 50%. Pathological examination of the specimen revealed "pleomorphic liposarcoma of the colon" (Figure 5). Although adjuvant chemotherapy and radiotherapy were recommended, the patient did not accept. After 12 months, the patient had recurrence of the disease. Abdominopelvic CT demonstrated a recurrent solid mass 4 cm in size at the ileocecal junction, invading the ureter, which caused hydroureteronephrosis. No metastasis was detected. Partial small bowel resection was performed. Pathological examination revealed "de-differentiated liposarcoma." He had six cycles of ifosfamide plus doxorubicin chemotherapy. Thirty months after chemotherapy, there was neither recurrence nor metastasis. The informed consent was given by the patient.

## Case 3

A 49-year-old woman experienced abdominal and lower back pain. An abdominal computed tomography showed a slightly enhancing solid mass, multiple metastatic lesions in the liver, and peritoneal metastases (Figure 6). Because of bowel obstruction, she underwent right hemicolectomy and omentectomy. Macroscopically, the tumor was approximately 20 cm in



**Figure 5. a-c.** Pathological examination shows lipoblasts with atypical, multivacuolated, and hyperchromatic nuclei among the pleomorphic spindle-shaped cells (H&E X200 magnification) **(a)**. After 1 year, small bowel resection material was infiltrated with de-differentiated tumor cells, predominantly spindle mesenchymal cells (H&E X100 magnification) **(b)**, positive immunostaining with S100 (DABX200) **(c)**.



**Figure 6.** Abdominopelvic CT shows multiple metastases in the liver.

size, and peritoneal dissemination was present. Microscopic examination revealed small round tumor cells with central, hyperchromatic nuclei and scant eosinophilic cytoplasm, involving the submucosal, mucosal, and subserosal layer of the colon. Immunohistochemically, desmin and vimentin showed paranuclear dot-like pattern positivity; smooth muscle actin, cytokeratin 20, Wilms tumor (WT-1), S-100, CD 117, and CD 34 staining was negative. Ki-67 labeling index was approximately 40%. Pathological examination of the specimen revealed "desmoplastic small round cell tumor of the colon" (Figure 7). After six courses of chemotherapy (vincristine, cyclophosphamide plus doxorubicin), abdominal computed tomography showed a partial response in the liver mass. The chemotherapy was continued as three cycles of vincristine, cyclophosphamide, and actinomycin. Eighteen months after diagnosis, the patient died from an acute purulent cholangitis. The written informed consent was obtained from the patient while she had chemotherapy.

## DISCUSSION

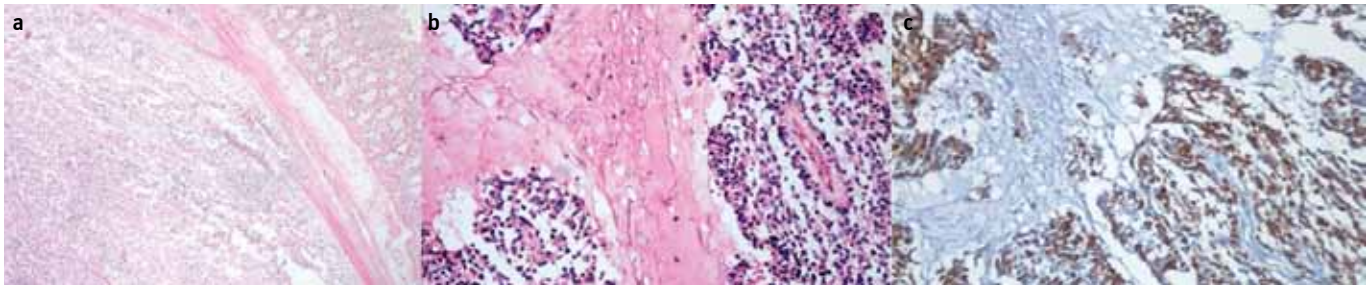
Primary mesenchymal tumors of the colon are a rare and heterogeneous group. Leiomyosarcoma arises from the blood muscles and smooth muscles of the muscular layer of the colon, whereas liposarcoma originates from adipose tissue. Desmoplastic small round cell tumors also arise from the mesothelium and demonstrate mesenchymal epithelial and neural

differentiation. Like mesenchymal tumors of the extremities or intraabdominal locations, tumor size, mitotic count, and presence of necrotic area are the most important prognostic factors (1-3). The symptoms of these rare tumors are based on tumor size and location of the tumor. Abdominal pain, rectal or intraabdominal bleeding, weight loss, constipation, diarrhea, bowel obstruction, tenesmus, anorexia, and fever are the most common signs and symptoms on presentation (1,3). The optimal diagnostic approach and treatment for primary mesenchymal tumors of the colon have not been defined due to the small number of published cases.

Leiomyosarcoma of the colon is an infrequent tumor that can cause intraluminal or extraluminal obstruction or perforation. Leiomyosarcoma occurs especially in young adults, but in older adults, the mean age of diagnosis is 50 years. The diagnosis can be established after surgery, because there is no specific symptom or diagnostic examination (4). On pathological examination, the histological grade, determined by the number of mitotic figures per field, is the most important criterion for leiomyosarcoma diagnosis. The c-KIT determination is negative, unlike gastrointestinal stromal tumors, whereas the immunohistochemical examination is positive for actin, vimentin, and desmin. Leiomyosarcoma is an aggressive tumor with a high local recurrence rate as well as significant hematogenous spread. A treatment protocol has not been established because of a lack of prospective randomized clinical trials. After complete resection, the most common treatment approach is anthracycline-based adjuvant chemotherapy for patients with large tumor size and high-grade tumors (1,3,5). Radiotherapy is a less effective treatment in leiomyosarcoma of the gastrointestinal tract. However, it has been reported that leiomyosarcoma can develop after radiotherapy (6). Herein, we presented a leiomyosarcoma of the colon, in which the patient was given anthracycline-based chemotherapy because of high grade.

Liposarcoma is a common sarcoma of the soft tissues in adults, and it occurs most commonly in the extremities and retroperitoneum. Liposarcoma rarely involves the gastrointestinal tract, and a primary liposarcoma of the colon is extremely uncommon. The prognosis of primary liposarcoma of the colon is not known. However, the pleomorphic type is a high-grade tumor and has a high mortality rate (7). Some important factors have





**Figure 7. a-c.** Pathological examination shows the infiltration of small round tumor cells under the intestinal mucosa (H&E X40 magnification) **(a)**. There is fibromyxoid/desmoplastic stroma among tumor cells islands (H&E X100 magnification) **(b)**. Immunohistochemical desmin examination shows paranuclear dot-like pattern of positivity (DABX100) **(c)**.

been shown as poor prognostic factors. These are age >45 years, presence of round cells, necrotic areas within the mass, and dissemination of the disease (8). Because very few cases of primary liposarcoma of the colon have been published, optimal treatment strategies have not been established yet. However, complete surgical resection should be performed. Neither radiotherapy nor chemotherapy has been shown to be as effective as standard therapy, but doxorubicin-based chemotherapy has been suggested for liposarcoma with high risk of relapse (9-11). The present case was a pleomorphic liposarcoma, in which the patient accepted no adjuvant therapy and had recurrence of the disease. After re-resection, doxorubicin-based chemotherapy was given.

Desmoplastic small round cell tumor is an aggressive malignant neoplasm that usually occurs in adolescents or young adults. Most tumors are confined to the abdomen. Microscopically, nests of small round cells within a desmoplastic stroma are observed. Immunohistochemical staining can show evidence of epithelial, myogenic, and neural marker expression. The tumor cells are strongly positive for keratin epithelial marker antigens, desmin, vimentin, and neuron-specific enolase, corresponding to pleomorphic differentiation and characteristic of desmoplastic small round cell tumor. The cell of origin remains unknown, but it is speculated that these tumors arise from the serosal lining cells. A specific chromosomal translocation, t (11; 22) (p13; q12), has been documented in desmoplastic small round cell tumor and is increasingly used to confirm the diagnosis (12,13). In our case, we could not perform the specific chromosomal translocation. Histologically, tumor cells consisted of small round-to-oval cells with paranuclear dot-like pattern expression of desmin. Because of metastatic disease and low performance status, we could not give intensive chemotherapy. After chemotherapy, metastases in the liver were decreased, but the patient died. It is known that the response of desmoplastic small round tumors to conventional chemotherapy is poor and that these tumors have high mortality rate (14,15).

In conclusion, leiomyosarcoma, liposarcoma, and desmoplastic small round cell tumor of the colon are rare but aggressive neoplasms with poor prognosis. Complete surgical resection has been suggested, if it can be performed. The location of

these tumors in the colon suggests gastrointestinal stromal tumor (GIST). Immunohistochemically, SMA, desmin, vimentin, S-100, neuron-specific enolase, CD34, and CD 117 should be used in the differential diagnosis of primary mesenchymal tumors. In GITs, S-100, neuron-specific enolase, CD34, and CD 117 are generally positive, whereas desmin and SMA are negative. Nonetheless, SMA and desmin are usually positive in primary mesenchymal tumors, but CD 117, CD34, S-100, and neuron-specific enolase are negative (16). Treatment protocols of primary mesenchymal tumors have not been established yet. The collection of a larger number of case studies is needed for the definition of guidelines for the management of these rare tumors.

**Ethics Committee Approval:** N/A.

**Informed Consent:** Written informed consent was obtained from patients who participated in this case.

**Peer-review:** Externally peer-reviewed.

**Author contributions:** Concept - A.Y., S.D.; Design - S.D.; Supervision - A.Y., G.G.D.; Resource - N.Ç.D., A.G.D.; Materials - N.Ç.D., B.T.; Data Collection&/or Processing - A.Y., S.D.; Analysis&/or Interpretation - A.Y.; Literature Search - A.G.D., B.T.; Writing - A.Y.; Critical Reviews - S.D., N.Ç.D.

**Conflict of Interest:** No conflict of interest was declared by the authors.

**Financial Disclosure:** The authors declared that this study has received no financial support.

## REFERENCES

1. Conlon KC, Casper ES, Brennan MF. Primary gastrointestinal sarcomas: analysis of prognostic variables. *Annals of Surgical Oncology* 1995; 2: 26-31. [\[CrossRef\]](#)
2. Lee CH, Jan YJ, Chen JT, Ho WL, Tseng CH, Wang J. Colorectal mesenchymal tumor: A clinicopathologic study of 25 cases. *J Chin Med Assoc* 2005; 68: 291-8. [\[CrossRef\]](#)
3. Nishimura J, Morii E, Takahashi T, et al. Abdominal soft tissue sarcoma: a multicenter retrospective study. *In J Clin Oncol* 2010; 15: 399-405. [\[CrossRef\]](#)
4. Iwasa K, Taniguchi K, Noguchi M, Yamashita H, Kitagawa M. Leiomyosarcoma of the colon presenting as acute suppurative peritonitis. *Surg Today* 1997; 27: 337-44. [\[CrossRef\]](#)
5. Gronchi A, Lo Vullo S, Fiore M, et al. Aggressive surgical policies in a retrospectively reviewed single institution case series of retroperitoneal soft tissue sarcoma patients. *J Clin Oncol* 2009; 27: 24-30. [\[CrossRef\]](#)

6. Mavrodontidis A, Zalavras C, Skopelitou A, Karavasilis V, Briasoulis E. Leiomyosarcoma as a second metachronous malignant neoplasm following colon adenocarcinoma. A case report and review of the literature. *Sarcoma* 2001; 5: 31-3. [\[CrossRef\]](#)
7. Downes KA, Goldblum JR, Montgomery EA, Fisher C. Pleomorphic liposarcoma: a clinicopathologic analysis of 19 cases. *Med Pathol* 2001; 14: 179-84. [\[CrossRef\]](#)
8. D'Annibale M, Cosimelli M, Covello R, Stasi E. Liposarcoma of the colon presenting as an endoluminal mass. *World J Surg Oncol* 2009; 7: 1-5. [\[CrossRef\]](#)
9. Jones RL, Fisher C, Al-Muderis O, Judson IR. Differential sensitivity of liposarcoma subtypes to chemotherapy. *Eur J Cancer* 2005; 41: 2853-56. [\[CrossRef\]](#)
10. Stander H, Tiresson I, Cavallin-Stahi E. A systematic overview of radiation therapy effects in soft tissue sarcomas. *Acta Oncol* 2003; 42: 516-31. [\[CrossRef\]](#)
11. Jarbouli S, Moussi A, Jarraya H, et al. Primary dedifferentiated liposarcoma of the colon: A case report. *Gastroenterol Clin Biol* 2009; 33: 1016-8. [\[CrossRef\]](#)
12. Gerald WL, Rosai J, Ladanyi M. Characterization of the genomic breakpoint and chimeric transcripts in the EWS-WT1 gene fusion of desmoplastic small round cell tumor. *Proc Nat Acad Sci U S A* 1995; 92: 1028-32. [\[CrossRef\]](#)
13. Nathan JD, Gingalewski C, Salem RR. Intra-abdominal desmoplastic small round cell tumor. *Yale J Biol Med* 2001; 74: 13-20.
14. Stuart-Buttle CE, Smart CJ, Pritchard S, Martin D, Welch IM. Desmoplastic small round cell tumour: A review of literature and treatment options. *Surg Oncol* 2008; 17: 107-12. [\[CrossRef\]](#)
15. Takahira K, Ohi S, Fujii N, et al. Intra-abdominal desmoplastic small round cell tumor (IDSRT). *J Gastroenterol* 2000; 35: 712-6. [\[CrossRef\]](#)
16. van Roggen JFG, van Velthuysen MLF, Hogendoorn PCW. The histopathological differential diagnosis of gastrointestinal stromal tumors. *J Clin Pathol* 2001; 54: 96-103. [\[CrossRef\]](#)