



Meckel's diverticulum detected by computed tomographic enterography: Report of 3 cases and review of the literature

SMALL INTESTINE

Jae Min Lee, Chan Dong Jeon, Seung Han Kim, Jong Soo Lee, Seung Joo Nam, Hyuk Soon Choi, Eun Sun Kim, Bora Keum

Department of Internal Medicine, Korea University College of Medicine, Seoul, Republic of Korea

ABSTRACT

Meckel's diverticulum is a common anomaly of the small intestine and occasionally presents as obscure gastrointestinal hemorrhage. Before operation, it is difficult to diagnose by imaging, especially in adults. Conventional abdominal computed tomography and endoscopy have limitations for the diagnosis of Meckel's diverticulum. Diagnostic methods in patients with small bowel lesions include enteroclysis, angiography, push enteroscopy, and capsule endoscopy; however, all of these techniques have low diagnostic yields to detect Meckel's diverticulum. Recently, computed tomographic enterography has been reliable in assessing small bowel disease. We present 3 cases of Meckel's diverticulum with bleeding in adults who were diagnosed by computed tomographic enterography. The bleeding source was not found in the total colonoscopy, and Tc-99m pertechnetate scans were negative in these patients. However, outpouching structures of the distal ileum with enhancement were detected by computed tomographic enterography. All patients underwent small bowel segmental resection. Meckel's diverticulum was confirmed by histopathology of the resected ileum segment, and the type of heterotopic tissue was gastric mucosa.

Keywords: Meckel's diverticulum, hemorrhage, CT enterography, adult

INTRODUCTION

Meckel's diverticulum (MD) is an embryologic abnormality that arises from incomplete closure of the omphalomesenteric, or vitelline, duct. It is the most common congenital anomaly of the small intestine, occurring in 2%-3% of the population (1). Most patients are asymptomatic; however, in those who develop symptoms, the disease can mimic other abdominal disorders, such as inflammatory bowel disease, gastrointestinal (GI) ulcers, and appendicitis. The complication rate was estimated at approximately 4% during the total lifetime (2). GI bleeding is a common complication in symptomatic MD patients. It is associated with ectopic tissues, such as gastric and pancreatic tissues, in the diverticulum. Tc-99m pertechnetate scintigraphy may be a feasible diagnostic tool for pediatric patients; however, the accuracy drops to below 50% in adults (3). Because of the difficulties in making the distinction between a diverticulum and intestinal

loops, conventional computed tomography (CT) is usually of little value.

Recently, CT enterography has been used for diagnosis of small intestine lesions. CT enterography differs from routine abdominal CT in that it utilizes enteric contrast agent for better display of the bowel lumen and wall (4). Here, we describe 3 cases of MD in patients who presented with obscure GI bleeding and were diagnosed by CT enterography.

CASE PRESENTATION

Case 1

A 25-year-old man was admitted to the hospital with dizziness and 6 episodes of hematochezia during 1 week. Physical examination demonstrated normal vital signs and a soft, distended abdomen with normoactive bowel sounds. Melena and bloody stools were appar-

Address for Correspondence: Bora Keum, Department of Internal Medicine, Korea University College of Medicine, Seoul, Republic of Korea
E-mail: borakeum@hanmail.net

Received: 27.8.2013 **Accepted:** 5.2.2014

© Copyright 2014 by The Turkish Society of Gastroenterology • Available online at www.turkjgastroenterol.org • DOI: 10.5152/tjg.2014.6044

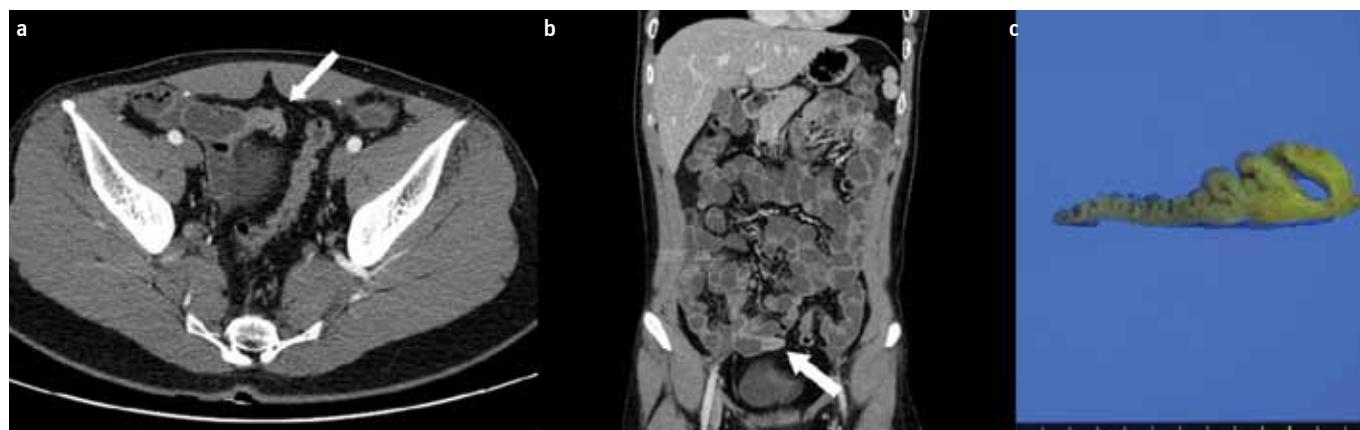

Figure 1. a-c. Patient 1, a 25-year-old man with hematochezia. CT enterography presents an outpouching structure with enhancement at the distal ileum (arrow) **(a, b)**. Pathologic specimen shows that Meckel's diverticulum measures 4.5 cm in length and 1.0 cm in diameter **(c)**.

Table 1. Patient characteristics and clinical data

Characteristics	Case 1	Case 2	Case 3
Age, years	25	34	17
Gender	Male	Male	Male
Symptom, GI bleeding			
Presentation	Hematochezia	Hematochezia	Hematochezia
Episode, numbers	6	2	2
Total amount of bleeding, mL	700	100	300
Initial Hb, g/dL	10.6	12.8	9.6
Initial Hematocrit, %	31	36.7	28.7
Diagnostic study (Small bowel)			
Capsule endoscopy	No lesion	No lesion	No lesion
Tc-99 m pertechnetate scan	Negative	Negative	Negative
CT enterography	Enhancing lesion	Enhancing lesion	Two enhancing lesions
Location of lesion	Distal ileum	Distal ileum	Distal ileum
Treatment	Small bowel resection	Small bowel resection	Small bowel resection
Type of heterotopic tissue	Gastric mucosa	Gastric mucosa	Gastric mucosa
Measurement of lesion size on CT enterography, cm	2.3×0.8	1.5×1.0	2.5×1.5 1.5×1.0
Resection specimen, cm	4.5×1.5	1.8×1.5	3.5×2.5 2.0×2.0
Bleeding recurrence after operation	No Recurrence	No Recurrence	No Recurrence

Hb: hemoglobin; GI bleeding: gastrointestinal bleeding; MD: Meckel's diverticulum; CT: computed tomography

ent in the digital rectal examination. Initial laboratory findings revealed hemoglobin 10.6 g/dL and hematocrit 31% (Table 1). Biochemical analysis and coagulation test results were within the normal range. Esophagogastroduodenoscopy showed no specific findings, except pale gastric mucosa. Total colonoscopy and capsule endoscopy did not present a bleeding focus. A Tc-99m pertechnetate scan was negative for ectopic gastric mucosa. However, in the CT enterography, an outpouching structure with a wall enhancement lesion was found at the pelvic ileal loop (Figure 1a). Informed consent was obtained before all procedures.

The patient underwent laparoscopically assisted small bowel segmental resection (Figure 1b). The resected specimen confirmed the presence of MD with heterotopic gastric mucosa. The postoperative course was uneventful.

Case 2

A 34-year-old man was transferred to the emergency department with 2 episodes of hematochezia during 2 days. Before admission, esophagogastroduodenoscopy and total colonoscopy had not identified the bleeding site at a primary care center. Physical examination was unremarkable. Initial

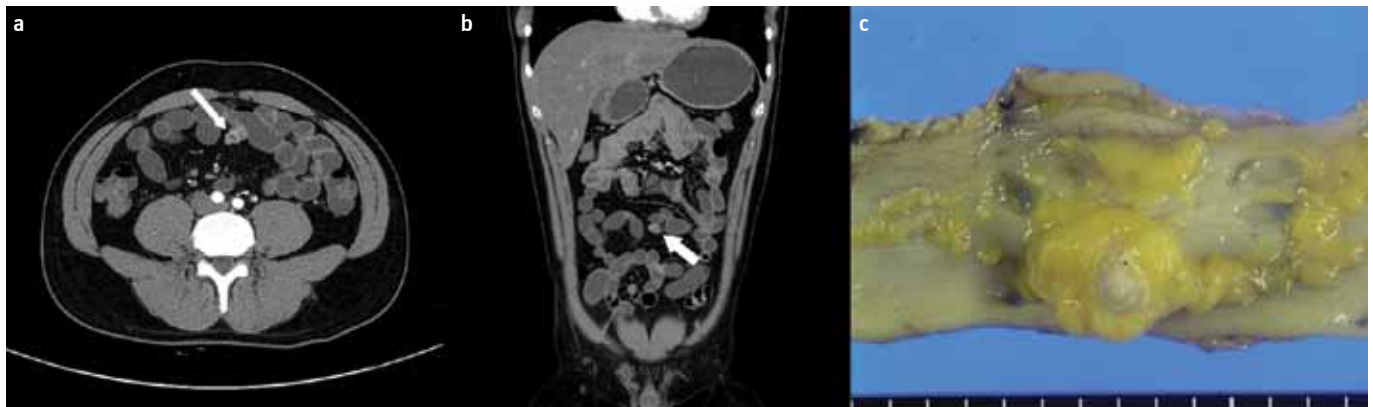


Figure 2. a-c. Patient 2, a 34-year-old man with hematochezia. CT enterography presents an outpouching structure with enhancement at the distal ileum (arrow) (**a, b**). Pathologic specimen shows that Meckel's diverticulum measures 1.8 cm in length and 0.8 cm in diameter (**c**).

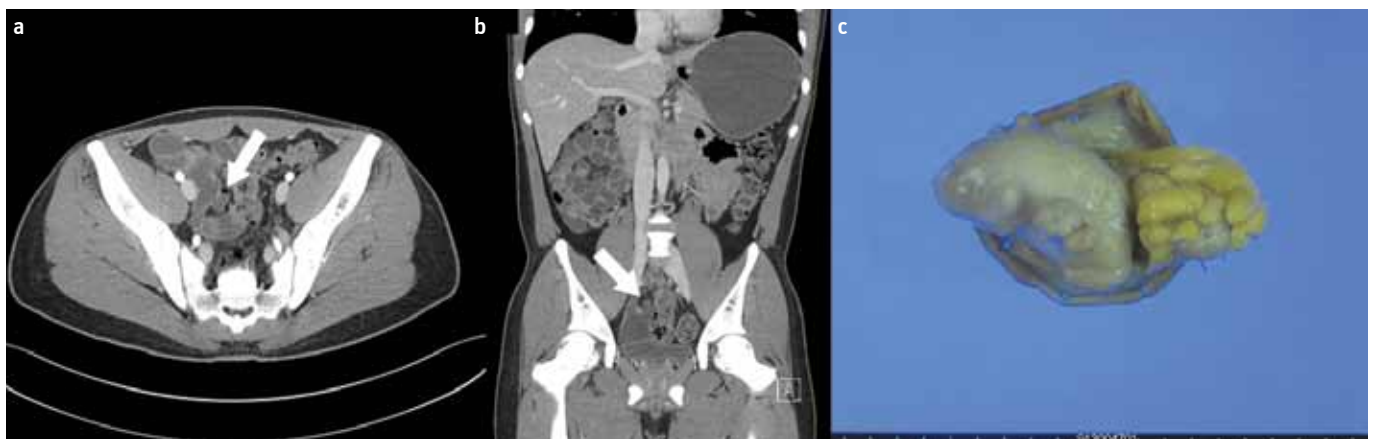


Figure 3. a-c. Patient 3, a 17-year-old man with hematochezia. CT enterography presents outpouching structures with enhancement at the distal ileum (arrow) (**a, b**). Pathologic specimen shows 2 Meckel's diverticula in the resected distal ileum. The larger diverticulum measures 3.5 cm in length and 2.0 cm in diameter. The other diverticulum measures 2.0 cm in length and 1.5 cm in diameter (**c**).

laboratory findings revealed hemoglobin 12.8 g/dL and hematocrit 36.7% (Table 1). Biochemical analyses demonstrated normal values. Because small bowel bleeding was suspected, capsule endoscopy and CT enterography were performed. Capsule endoscopy showed mild jejunal erosion; however, the bleeding point was not found. CT enterography presented the outpouching structure with a wall enhancement on the ileal loop (Figure 2a). The Tc-99m pertechnetate scan was negative for ectopic gastric mucosa. Informed consent was obtained before all procedures.

The patient underwent laparoscopically assisted small bowel segmental resection (Figure 2b). The resected specimen confirmed the presence of MD with focal bulging of the serosal surface. There was no recurrence of bleeding after surgery.

Case 3

A 17-year-old man was admitted to the hospital for evaluation of hematochezia. Over 2 weeks, he had 2 episodes of blood clots in his stool. Physical examination revealed normal vital signs and a soft, distended abdomen with normoactive bowel sounds. Initial laboratory findings revealed hemoglobin 9.6 g/dL and hematocrit 28.7% (Table 1). Other laboratory data

were unremarkable. Esophagogastroduodenoscopy and total colonoscopy had not identified the bleeding site. MD was suspected; however, the Tc-99m pertechnetate scan was negative for ectopic gastric mucosa. Capsule endoscopy did not present the bleeding focus, either. CT enterography was performed, and 2 outpouching lesions with small blind ends were discovered in the distal ileum (Figure 3a). Informed consent was obtained before all procedures.

Thus, laparoscopically assisted small bowel segmental resection was performed. Surgical resection of the ileal segment confirmed the presence of 2 diverticula with ectopic gastric mucosa (Figure 3b). The patient recovered uneventfully, and no additional episodes of hematochezia were noted in the outpatient department follow-up.

DISCUSSION

Meckel's diverticulum, which was first described by Fabricius Hildanus in 1598, is the most common malformation of the small intestine (5). Several small bowel anomalies, including MD, result from incomplete obliteration of the vitelline duct during the embryonic period (1). It is approximately 2 inches long, a true diverticulum composed of whole layers of normal

intestinal wall, and usually found approximately 2 feet from the ileocecal valve. Heterotopic tissues are usually contained in the diverticulum, which can induce GI bleeding. MD is predominant in men, with a male-to-female ratio of approximately 3:2 and a median age range of 23 years (6,7). It is often clinically asymptomatic, particularly in adults. However, MD can present with several GI manifestations, such as GI bleeding, bowel obstruction, diverticulitis, or perforation. Approximately 4% of MD patients develop a complication during their lifetime (2).

Conventional imaging studies, such as ultrasonography and abdominal CT, may suggest a diagnosis of MD; however, these findings are usually nonspecific. The patient with suspicious MD bleeding can be investigated with a Tc-99 m pertechnetate scan, which identifies the heterotopic gastric mucosa within the diverticulum. However, MD without ectopic gastric mucosa will not be visible on a Tc-99m pertechnetate scan. Diagnostic methods in patients with obscure GI bleeding include enteroclysis, angiography, push enteroscopy, and capsule endoscopy for the evaluation; all of these techniques are relatively insensitive and have low diagnostic yields to detect MD in the small bowel (8). Recent studies have suggested that CT enterography is a useful method for diagnosis of small bowel lesions (9,10). CT enterography is easily accessible and minimally invasive and requires relatively short examination times.

The treatment of choice in complicated MD patients is surgical resection. For patients undergoing operation due to MD bleeding, a segmental small bowel resection rather than simple diverticulectomy is usually recommended (11).

Ethics Committee Approval: N/A.

Informed Consent: Written informed consent was obtained from patients who participated in this case.

Peer-review: Externally peer-reviewed.

Author contributions: Concept - B.K.; Design - B.K., J.M.L.; Supervision - B.K., E.S.K., H.S.Ch.; Resource - B.K.; Materials - B.K.; Data Collection&/or

Lee et al. Usefulness of computed tomographic enterography

Processing - J.M.L., C.D.J., S.H.K., J.S.L., S.J.N.; Analysis&/or Interpretation - J.M.L., C.D.J.; Literature Search - J.M.L., C.D.J., H.S.C., E.S.K., B.K.; Writing - J.M.L.; Critical Reviews - H.S.C., E.S.K., B.K.

Conflict of Interest: No conflict of interest was declared by the authors.

Financial Disclosure: The authors declared that this study has received no financial support.

REFERENCES

1. Moore TC. Omphalomesenteric duct malformations. *Semin Pediatr Surg* 1996; 5: 116-23.
2. Leijonmarck CE, Bonman-Sandelin K, Frisell J, Räf L. Meckel's diverticulum in the adult. *Br J Surg* 1986; 73: 146-9. [\[CrossRef\]](#)
3. Schwartz MJ, Lewis JH. Meckel's diverticulum: Pitfalls in scintigraphic detection in the adult. *Am J Gastroenterol*. 1984; 79: 611-8.4.
4. Paulsen SR, Huprich JE, Fletcher JG, et al. CT enterography as a diagnostic tool in evaluating small bowel disorders: Review of clinical experience with over 700 cases. *Radiographics* 2006; 26: 641-57. 5.
5. Uppal K, Tubbs RS, Matusz P, et al. Meckel's diverticulum: a review. *Clinical anatomy*. 2011;24:416-22. [\[CrossRef\]](#)
6. Mackey WC, Dineen P. A fifty year experience with Meckel's diverticulum. *Surgery, gynecology & obstetrics*. 1983;156:56-64.
7. Cullen JJ, Kelly KA, Moir CR, et al. Surgical management of Meckel's diverticulum. An epidemiologic, population-based study. *Annals of surgery*. 1994;220:564-8; discussion 8-9. [\[CrossRef\]](#)
8. Filippone A, Cianci R, Milano A, et al. Obscure and occult gastrointestinal bleeding: comparison of different imaging modalities. *Abdominal imaging*. 2012;37:41-52. [\[CrossRef\]](#)
9. Elsayes KM, Al-Hawary MM, Jagdish J, et al. CT enterography: principles, trends, and interpretation of findings. *Radiographics : a review publication of the Radiological Society of North America, Inc*. 2010;30:1955-70. [\[CrossRef\]](#)
10. Sodhi JS, Zargar SA, Rashid W, et al. 64-section multiphase CT enterography as a diagnostic tool in the evaluation of obscure gastrointestinal bleeding. *Indian journal of gastroenterology : official journal of the Indian Society of Gastroenterology*. 2012;31:61-8. [\[CrossRef\]](#)
11. Arnold JF, Pellicane JV. Meckel's diverticulum: a ten-year experience. *The American surgeon*. 1997;63:354-5.