



## Spontaneous giant splenic hydatid cyst rupture causing fatal anaphylactic shock: A case report and brief literature review

Sedat Belli<sup>2</sup>, Sami Akbulut<sup>1</sup>, Gürcan Erbay<sup>3</sup>, Nazım Emrah Koçer<sup>4</sup>

<sup>1</sup>Department of General Surgery, Diyarbakır Education and Research Hospital, Diyarbakır, Turkey

<sup>2</sup>Department of General Surgery, Başkent University Faculty of Medicine, Adana, Turkey

<sup>3</sup>Department of Radiology, Başkent University Faculty of Medicine, Adana, Turkey

<sup>4</sup>Department of Pathology, Başkent University Faculty of Medicine, Adana, Turkey

### ABSTRACT

Hydatid disease is a parasitic infection characterized by cyst formation in any organ, although the liver and lungs are most commonly involved. Hydatid disease of the spleen is uncommon, representing <8% of all human hydatid diseases. Splenic hydatid cysts usually coexist with liver hydatid cysts (secondary form), although the spleen is the primary location (primary form) in some cases. The clinical signs and symptoms of splenic hydatid cysts depend on their size, relationship with adjacent organs, and complications. One of the complications of splenic hydatid cysts is cyst rupture either after trauma or spontaneously as a result of increased intracystic pressure. These cysts may rupture into a hollow organ, through the diaphragm into the pleural cavity, or directly into the peritoneal cavity. A splenic hydatid cyst that ruptures into the peritoneal cavity may cause complications, including signs of peritoneal irritation, urticaria, anaphylaxis, and death, as in our case. Therefore, a hydatid cyst rupture requires both emergency surgery and careful postoperative care. In this study, we present a case of a giant splenic hydatid cyst that ruptured into the peritoneal cavity without any trauma. A review of cases reported in the English literature about splenic hydatid cyst perforation is also discussed.

**Keywords:** Hydatid cyst, anaphylactic shock, mortality, spleen

### INTRODUCTION

Cystic echinococcosis, also known as a hydatid cyst, is an infection that still constitutes a serious problem in endemic regions, particularly in the Middle East, Far East, Mediterranean, South America, and Australia. It is a parasitic infestation caused by the larval stage of *Echinococcus granulosus* (1-10). Hydatid cysts may develop in any body organ but occur most frequently in the liver (50-77%) and lungs (18-35%) and occasionally in other organs, such as the spleen (0.5-8%) (1,2).

A splenic hydatid cyst (SHC), first reported by Berthelot in 1790, is an extremely rare disease, even in endemic areas, including Turkey (3,4). SHCs are divided into primary and secondary forms (4). The clinical signs and symptoms of SHCs depend on their size, relationship with adjacent organs, and complications. One of the common

complications of hydatid disease is cyst rupture after trauma or spontaneous rupture as a result of increased intracystic pressure. (1,5). SHCs may rupture into a hollow organ, through the diaphragm into the pleural cavity, or directly into the peritoneal cavity. SHCs that rupture into the peritoneal cavity may cause complications, including signs of peritoneal irritation, urticaria, anaphylaxis, and death. Therefore, hydatid cyst rupture requires both emergency surgery and careful postoperative care. In this study, we present a case of a giant SHC that ruptured into the peritoneal cavity without trauma.

### CASE PRESENTATION

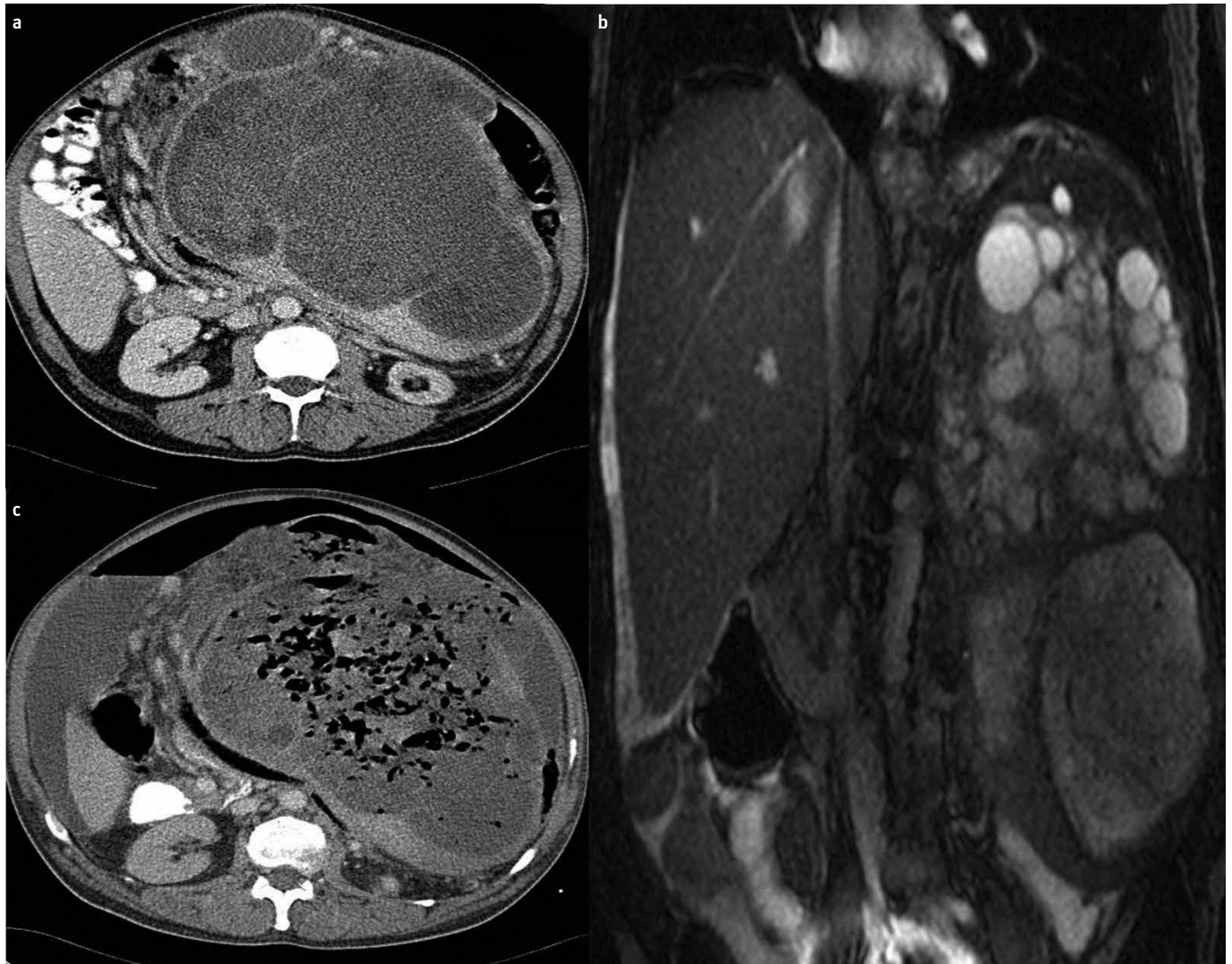
A 56-year-old male patient was admitted to our outpatient polyclinic, complaining of weakness, fatigue, and abdominal pain and swelling. He had undergone an evaluation for these complaints at another center,

**Address for Correspondence:** Sedat Belli, Department of Surgery, Başkent University Faculty of Medicine, Adana, Turkey

E-mail: sedatbelli@hotmail.com E-mail: akbulutsami@gmail.com

**Received:** 217.4.2012 **Accepted:** 26.8.2012

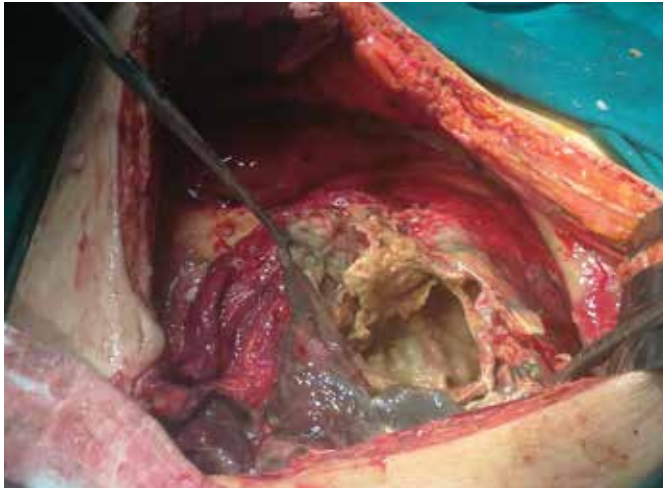© Copyright 2014 by The Turkish Society of Gastroenterology • Available online at [www.turkjgastroenterol.org](http://www.turkjgastroenterol.org) • DOI: 10.5152/tjg.2014.3521



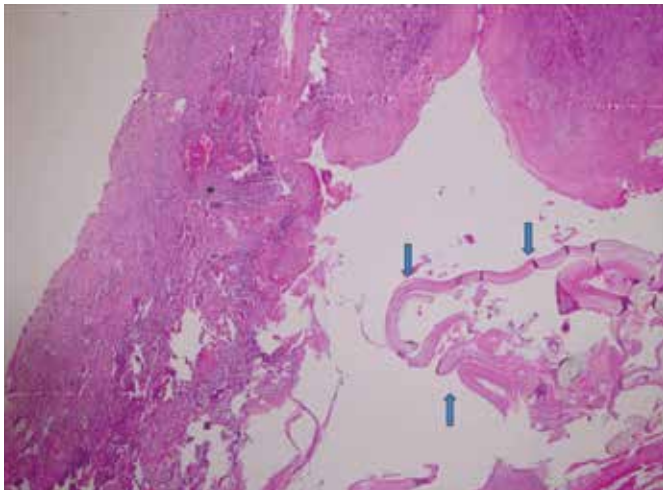
**Figure 1. a-c.** A primary hydatid cyst that was lobulated with exophytic contours and daughter cysts, originated from the spleen, and extended to the pelvic region. Contrast-enhanced axial computed tomography (CT) image (**a**) and coronal T2-weighted magnetic resonance images (**b**). After hospitalization for the operation, the splenic hydatid cyst ruptured spontaneously; free air-fluid labeling was seen within the cyst and peritoneal cavity on an axial contrast-enhanced CT image (**c**).

which had revealed anemia and elevated liver function tests. A physical examination revealed a distended abdomen on inspection, along with a palpable mass extending through the midline into the left hypochondriac region. Anemia (hemoglobin: 8.3 g/dL) and elevated liver function (total bilirubin/direct bilirubin: 2.27/1.62; alkaline phosphatase/gamma glutamyl transferase: 497/440) were detected on routine laboratory tests. In the computed tomography (CT) evaluation, a giant 30x20-cm splenic hydatid cyst was found that occupied the entire left hypochondrium as well as the mid-abdomen to the pelvis and contained calcifications (Figure 1a). The stomach had been shifted to the right of midline due to the mass effect. The body and tail of the pancreas had been pushed caudally. Magnetic resonance cholangiopancreatography was performed due to the elevated bilirubin levels and revealed that the cystic mass of splenic origin was impinging on the choledoc duct (Figure 1b). The patient was then hospitalized in the clinic for further preoperative preparation. On the second day of hospitalization, the

patient developed findings suggestive of anaphylactic shock, such as severe abdominal pain, tachycardia, hypotension, and widespread erythema, and was subsequently transferred to the intensive care unit to implement resuscitation. Abdominal CT images depicted free air and fluid within the abdominal cavity (Figure 1c). Diagnosed with a cyst rupture, the patient underwent an emergency surgical operation. The abdominal cavity was entered through a midline incision. During the surgical exploration, a 30x20 perforated giant cystic lesion with calcified borders was detected, which stemmed from the spleen, compressed the stomach and colon, and extended down to the pelvis. There appeared to be voluminous intra-abdominal fluid and a sizable number of daughter vesicles released into the abdominal cavity when the cyst ruptured (Figure 2). Total excision of the cyst together with the spleen was performed, during which an iatrogenic injury of the descending colon occurred upon releasing the fairly dense adhesions to the surrounding tissues. Thus, a Hartmann-style end colostomy was created. The operation was



**Figure 2.** Intraoperative view of the ruptured giant splenic hydatid cyst.



**Figure 3.** Photomicrograph reveals the lamellar membrane of the hydatid cyst (arrows) surrounded by fibrosis and a mononuclear inflammatory infiltrate containing multinucleated giant cells (asterisk) (HE X40).

terminated with the insertion of two drains-one into the splenic lodge and the other into the pelvic cavity-preceded by washing of the entire abdominal cavity with 10 L of saline solution. The intubated patient was transferred postoperatively to the intensive care unit. Despite effective cardiopulmonary resuscitation, the patient, whose general clinical status deteriorated, died on Day 3 of postoperative follow-up. A histopathological examination of the surgical specimen showed the lamellar membrane of the hydatid cyst surrounded by fibrosis and a mononuclear inflammatory infiltrate containing multinucleated giant cells (Figure 3). Informed consent was taken from patient's relative.

## DISCUSSION

Splenic hydatid cyst occurs in 1.5-3.5% of all cases of abdominal echinococcosis across all ages and in both sexes (1,3-5,7-9). SHCs usually coexist with liver hydatid cysts (secondary); however, in some cases, the spleen is the primary location (4,10). Splenic infestation usually occurs through an arterial route when the parasite has passed through two other filters: hepatic and pulmonary (3,6,7). SHCs may also develop by retrograde spread from

the liver into the spleen via the hepatic portal and splenic veins in patients with portal hypertension. The spleen may also be affected by rupture of a hydatid cyst into the peritoneal cavity (4,6).

The clinical signs and symptoms of SHCs depend on location, size, relation to adjacent organs, and complications, such as after trauma or spontaneously as a result of increased intracystic pressure. Pressure effects and perforation to the adjacent organs are more frequently observed in giant hydatid cysts (11-14). The most common clinical signs and symptoms are splenomegaly, abdominal lump, dull dragging ache, dyspepsia, constipation due to pressure on the colon, and dyspnea due to pushing up of the left diaphragm. Some patients may present with complications, such as infection of the cyst; rupture of the cyst into the peritoneal or pleural cavity; fistula formation into hollow organs, like the colon or stomach; rupture of longstanding SHC into the bronchial tree; splenothoracic fistula; sympathetic pleural effusion; calcification; hypersplenism; or signs of anaphylactic shock (4,6,11).

Anaphylactic reactions and shock due to rupture of a hydatid cyst are well known severe complications in patients with hydatid disease (6,7). In our literature search that was performed using the keywords "spleen," "hydatid cyst," "perforation," "rupture," and various combinations of these terms in the PubMed and Google Scholar databases, we found only five articles on the perforation of a splenic hydatid cyst (1,10-13). Six cases, ranging in age from 8 to 77 years, have been reported. Five of the cases were complicated by a free intraperitoneal perforation, whereas fistulization into the colon developed in one. Mortality occurred in none of the patients.

The diagnosis of SHC is based on historical and geographic backgrounds, a physical examination, radiological tools, serology, fine needle aspiration cytology (FNAB), and histopathological examinations of resected cysts. Serological tests are used for diagnosis, screening, and follow-up for recurrence.

The differential diagnoses of SHC include non-parasitic cysts and tumors of the diaphragm, stomach, colon, left kidney, or pancreas. Non-parasitic cysts can be divided into primary (true cysts) and secondary (pseudo-cysts).

Surgery remains the main treatment for both ruptured and uncomplicated SHCs (3). The main goals of surgery, especially complicated cases, are to prevent complications; eliminate local disease; and minimize morbidity, mortality, and recurrence rates. It remains controversial whether a total splenectomy is more beneficial than a spleen-preserving approach in patients with SHCs. A splenectomy is advocated by the majority of surgeons, as it provides minimal risk for recurrence. However, splenectomy is associated with sepsis-related deaths in 1.9% of adults and 4% of children. Thus, conservative surgical procedures have been increasingly proposed, including partial splenectomy, enucleation, de-roofing with omentoplasty, internal drainage with



cystojejunal anastomosis, or external drainage (3,13). An alternative to surgery is percutaneous drainage and administration of a sclerosing agent, such as 96% alcohol and 1% povidone iodine under ultrasonography guidance (3,9). One of the problems likely to be encountered with this method is intraperitoneal spillage of the cystic contents during the procedure, and another other is recurrence of the disease. Moreover, the rates of anaphylactic reactions occurring during percutaneous treatment are similar to that of open surgery (9).

After intervention for a ruptured cyst, the most important step is irrigating the peritoneal cavity with sufficient scolicalid agents and careful, patient removal of all cystic contents. Scolicalid agents include cetrimide-chlorhexidine, povidone iodine (10%), silver nitrate (0.5%), hypertonic saline solution (3-30%), chlorhexidine (0.4%), and praziquantel. As patients with traumatic or spontaneous cyst rupture often require emergency surgery, they can not receive antihelminthic medical treatment preoperatively. The literature suggests that medical treatment should start as early as possible postoperatively and continue for 1-6 months, based on the circumstances, to reduce the recurrence rate. Patients with uncomplicated hydatid cysts should be followed with ultrasonography (US) examinations and indirect haemagglutination (IHA) tests starting 6 months postoperatively and every 1-2 years thereafter. Those with perforated cysts should be followed at shorter intervals.

In summary, a hydatid cyst should always be considered in the differential diagnosis of patients who live in endemic areas and in whom spleen cystic lesions are detected. Surgery should be planned for larger cysts, which actually carry a greater risk for complications, such as perforation, infection of the cyst, and fistula formation into hollow organs.

**Ethics Committee Approval:** N/A.

**Informed Consent:** Written informed consent was obtained from patient who participated in this case.

**Peer-review:** Externally peer-reviewed.

**Author contributions:** Concept - S.B., S.A.; Design - S.B., S.A.; Supervision -S.B.; Resource - S.A.; Materials - S.B., G.E., N.E.K.; Data Collection&/or Processing - S.B.; Analysis&/or Interpretation - S.A., S.B.; Literature Search - S.A.; Writing - S.A.; Critical Reviews - S.B.

**Conflict of Interest:** No conflict of interest was declared by the authors.

**Financial Disclosure:** The authors declared that this study has received no financial support.

## REFERENCES

1. Dirican A, Yilmaz M, Unal B, et al. Ruptured hydatid cysts into the peritoneum: a case series Eur J Trauma Emerg Surg 2010; 36: 375-9.
2. Akbulut S, Senol A, Ekin A, Bakir S, Bayan K, Dursun M. Primary retroperitoneal hydatid cyst: report of 2 cases and review of 41 published cases. Int Surg 2010; 95: 189-96.
3. Rodríguez-Leal GA, Morán-Villota S, Milke-García Mdel P. Splenic hydatidosis: a rare differential diagnosis in a cystic lesion of the spleen. Rev Gastroenterol Mex 2007; 72: 122-5.
4. Malik AA, ul Bari S, Younis M, Wani KA, Rather AA. Primary splenic hydatidosis. Indian J Gastroenterol 2011; 30: 175-7. [\[CrossRef\]](#)
5. Derici H, Tansug T, Reyhan E, Bozdog AD, Nazli O. Acute intraperitoneal rupture of hydatid cysts. World J Surg 2006; 30: 1879-83. [\[CrossRef\]](#)
6. Culafic DM, Kerkez MD, Mijac DD, et al. Spleen cystic echinococcosis: clinical manifestations and treatment. Scand J Gastroenterol 2010; 45: 186-90. [\[CrossRef\]](#)
7. Mokhtari MAM, Spoutin A. Splenic hydatid cyst and relevance with anaphylaxis. Research Journal of Medical Sciences 2008; 2: 248-250.
8. Wani RA, Malik AA, Chowdri NA, Wani KA, Naqash SH. Primary extra-hepatic abdominal hydatidosis. Int J Surg 2005; 3: 125-7. [\[CrossRef\]](#)
9. Ormeci N, Soykan I, Palabiyikoglu M, et al. A new therapeutic approach for treatment of hydatid cysts of the spleen. Dig Dis Sci 2002; 47: 2037-44. [\[CrossRef\]](#)
10. Limas C, Soultanidis C, Kirmanidis MA, et al. Management of abdomen hydatidosis after rupture of a hydatid splenic cyst: a case report. Cases J. 2009; 2: 8416. [\[CrossRef\]](#)
11. Take Z, Yagci AB, Attala AO, et al. Splenic hydatid cyst perforating into the colon manifesting as acute massive lower gastrointestinal bleeding: an unusual presentation of disseminated abdominal echinococcosis. Singapore Med J 2008; 49: e113-6.
12. Passomenos D, Filippou D, Makrodimitri P, et al. Direct rupture of splenic hydatid cyst without volume loss: report of a unique case. Folia Med (Plovdiv) 2007; 49: 22-4.
13. Erel S, Kilicoglu B, Kismet K, Gollu A, Akkus MA. Peritoneal hydatid cyst perforation: a rare cause of emergency abdominal surgeries. Adv Ther 2008; 25: 943-50. [\[CrossRef\]](#)
14. Vasilescu C, Tudor S, Popa M, Tiron A, Lupescu I. Robotic partial splenectomy for hydatid cyst of the spleen. Langenbecks Arch Surg 2010; 395: 1169-74. [\[CrossRef\]](#)