

tomy. The calcified lesion was compatible with inactive hydatid cyst. The cholecystectomy was finished uneventfully. Before sending the specimen to the pathology laboratory, we cut the wall of the gallbladder and saw the hydatid cysts (Figure 2). The patient was discharged on postoperative day one and placed on 400 mg/day albendazole treatment. Chronic inflammation and hydatid cyst membranes were observed in the histopathological evaluation of the gallbladder.

E. granulosus is responsible for hydatid disease, most commonly in the liver. This infection is usually seen in sheep- and cattle-raising regions. Cholangitis with obstructive jaundice is a rare and dreadful complication of hydatid cysts ruptured into the biliary tract. In addition to the diagnostic capabilities of ERCP, it is a treatment tool for obstructive pathologies of the bile duct (1,2). ERCP

shows a cystobiliary relationship, and we did not observe any communication between the gallbladder and the calcified cystic lesion in the liver (3). A false-positive result of the serologic analysis should be kept in mind in patients with previous hydatid disease and no evidence of the disease currently (4). In this case, choledocholithiasis had been concluded as a main cause of the obstructive jaundice after ERCP preoperatively. In such patients, laparoscopic cholecystectomy is the best treatment strategy for preventing further cholangitis attacks. After surgery, macroscopic and pathologic findings revealed a cyst hydatid disease of the gallbladder in the patient, which is a very rare clinical entity (5). ERCP is used to diagnose and treat biliary pathologies. Removal of the gallbladder reduces further risks causing obstructive jaundice and helps in the definitive diagnosis.

REFERENCES

1. McManus DP, Zhang W, Li J, Bartley PB. Echinococcosis. Lancet 2003; 362: 1295-304.
2. Tarcin O. Rupture of hydatid cyst into the biliary tract. Gastrointest Endosc 2006; 63: 325-6.
3. Dziri C, Haoet K, Fingerhut A, Zaouche A. Management of cystic echinococcosis complications and dissemination: where is the evidence? World J Surg 2009; 33: 1266-73.
4. Pfister M, Gottstein B, Cerny T, Cerny A. Immunodiagnosis of echinococcosis in cancer patients. Clin Microbiol Infect 1999; 5: 693-7.
5. Safioleas M, Stamoulis I, Theocharis S, et al. Primary hydatid disease of the gallbladder: a rare clinical entity. J Hepatobiliary Pancreat Surg 2004; 11: 352-6.

Metin ERTEM, Erman AYTAÇ,
Zekeriya KARADUMAN

Department of General Surgery, İstanbul University
Cerrahpaşa Medical Faculty, İstanbul

A rare PRSS1 mutation in a Turkish family with hereditary chronic pancreatitis

Hereditär kronik pankreatiti olan bir Türk ailede nadir bir PRSS1 mutasyonu

To the Editor,

Hereditary pancreatitis (HP) is an autosomal dominant-inherited disorder characterized by recurrent attacks of pancreatitis with the development of chronic pancreatitis in the absence of known etiologic factors (1,2). R122H and N29I mutations

are the most common PRSS1 mutations that play a causal role in chronic pancreatitis worldwide (3-5). Herein, we report a rare PRSS1 mutation causing typical HP in a Turkish family. The polymorphism is called D21A and results in a substi-

Address for correspondence: Barış YILMAZ

Department of Gastroenterology, Dışkapı Yıldırım Beyazıt Educational and Research Hospital, Ankara, Turkey
E-mail: dryilmazb@gmail.com

Manuscript received: 14.02.2012 Accepted: 05.06.2012

doi: 10.4318/tjg.2012.0545

tution of alanine by aspartic acid at amino acid position 21. To the best of our knowledge, there are few reports of a D21A polymorphism in patients with HP in the medical literature (6).

A 30-year-old male patient was admitted with acute abdominal pain radiating to the back, nausea and mild fever. Physical examination revealed abdominal tenderness in the epigastric region. The clinical history revealed many episodes during the previous five years, some treated at home. Laboratory tests were within normal ranges, except for high serum levels of serum amylase, C-reactive protein (CRP) and erythrocyte sedimentation rate (ESR). Abdominal ultrasound showed increased pancreatic volume with diffuse edema, and the biliary tree was normal. Based on the clinical and laboratory findings of the patient, the diagnosis of acute pancreatitis was made. In the follow-up of the patient with medical treatment, clinic and laboratory improvement was observed. Magnetic resonance imaging (MRI) of the pancreas was performed one month after discharge from the hospital. MRI showed chronic pancreatitis findings (pancreatic parenchymal calcifications, pancreatic ductal irregularities and dilatations). All the etiologic factors of chronic pancreatitis (alcohol, hypercalcemia, hyperlipidemia, obstructive, and autoimmune, etc.) were excluded. In his family history, his elder sister and his father had experienced recurrent attacks of pancreatitis as well. The family pedigree is shown in Figure 1. The sequencing analysis comprised the entire coding region of PRSS1, including the intron-exon boundaries of each exon, and was performed on an

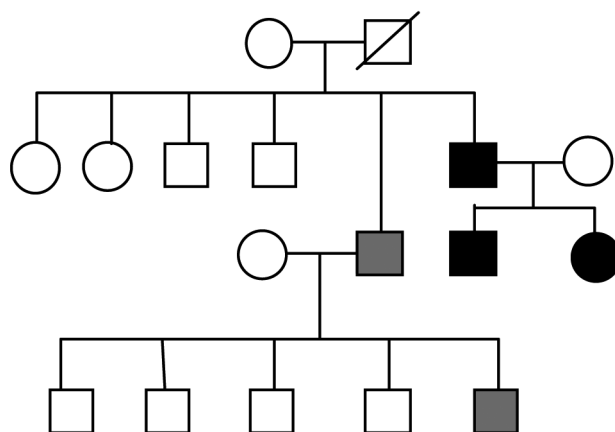


Figure 1. Pedigree of the chronic HP family with D21A polymorphism. Dark square: Male with D21A polymorphism and chronic HP. Dark round: Female with D21A polymorphism and chronic HP. Gray square: Male with chronic pancreatitis but D21A polymorphism is unknown. Hollow square: Normal male. Hollow round: Normal female. Lined square: Exitus male and D21A polymorphism and chronic HP is unknown.

ABI 3100 genetic analyzer. All three patients were found to be heterozygotes for the D21A mutation in the PRSS1 gene. DNA isolated from peripheral blood samples was analyzed for CFTR gene mutations by the reverse-hybridization method using INNO-LiPA CFTR assay test strips, and no CFTR mutations were found.

In conclusion, in light of our case, D21A polymorphism in the cationic trypsinogen (PRSS1) gene seems to be a risk factor for HP. In addition to the most commonly seen R122H and N29I mutations, the D21A mutation should be kept in mind in patients presenting with chronic HP.

REFERENCES

1. Lowenfels A, Maisonneuve P, DiMagno E, et al. Hereditary pancreatitis and the risk of pancreatic cancer. *J Natl Cancer Inst* 1997; 89: 442-6.
2. Perrault J. Hereditary pancreatitis. *Gastroenterol Clin North Am* 1994; 23: 743-52.
3. Whitcomb DC, Gorry MC, Preston RA, et al. Hereditary pancreatitis is caused by a mutation in the cationic trypsinogen gene. *Nat Genet* 1996; 14: 141-5.
4. Gorry MC, Gabbai Z, Furey W, et al. Mutations in the cationic trypsinogen gene are associated with recurrent acute and chronic pancreatitis. *Gastroenterology* 1997; 113: 1063-8.
5. Teich N, Mössner J, Keim V. Mutations of the cationic trypsinogen in hereditary pancreatitis. *Hum Mutat* 1998; 12: 39-43.
6. Nemoda Z, Sahin-Toth M. The tetra-aspartate motif in the activation peptide of human cationic trypsinogen is essential for autoactivation control but not for enteropeptidase recognition. *J Biol Chem* 2005; 280: 29645-52.

Barış YILMAZ¹, Fuat EKİZ¹, Ekrem KARAKAŞ³, Ayça AYKUT², Zahide ŞİMŞEK¹, Şahin ÇOBAN¹, Hüseyin ONAY², Ferda ÖZKINAY²

Department of ¹Gastroenterology, Dışkapı Yıldırım Beyazıt Educational and Research Hospital, Ankara

Department of ²Genetic, Ege University Medical School, İzmir

Department of ³Radiology, Harran University Medical School, Şanlıurfa