

Isolated dysphagia due to aquaporin-4 autoimmunity

Aquaporin-4 otoimmünitesine bağlı izole disfaji

To the Editor,

Neuromyelitis optica (NMO) is an inflammatory, demyelinating disease that affects the spinal cord and optic nerves and is associated with aquaporin-4 antibodies (Aqp-4 Ab) (1,2). NMO patients might occasionally present with medulla symptoms such as hiccups, nausea and vomiting and with small lesions in the dorsal medulla, which corresponds to a site of high Aqp-4 expression (2,3).

A 42-year-old female was referred to us with a three-week history of intractable hiccups, nausea and vomiting. She had undergone an attack of optic neuritis and transverse myelitis one year ago. Her physical and neurological examinations, routine blood tests, upper gastrointestinal endos-

copy, and cranial and spinal magnetic resonance imaging (MRI) with gadolinium enhancement were normal. Ten days later, she developed a sudden respiratory arrest, was intubated and her symptoms resolved spontaneously in one week. Thirty-six days later, she admitted with a two-day history of dysphagia. Her uvula was in the midline, the soft palate did not elevate on phonation, and the gag reflex could not be elicited. The neurological examination was otherwise normal. The T2-weighted cranial MRI sections revealed a large hyperintense lesion in the medulla oblongata (Figure 1). The cerebrospinal fluid examination showed lymphocytosis ($24/\text{mm}^3$), increased protein (54

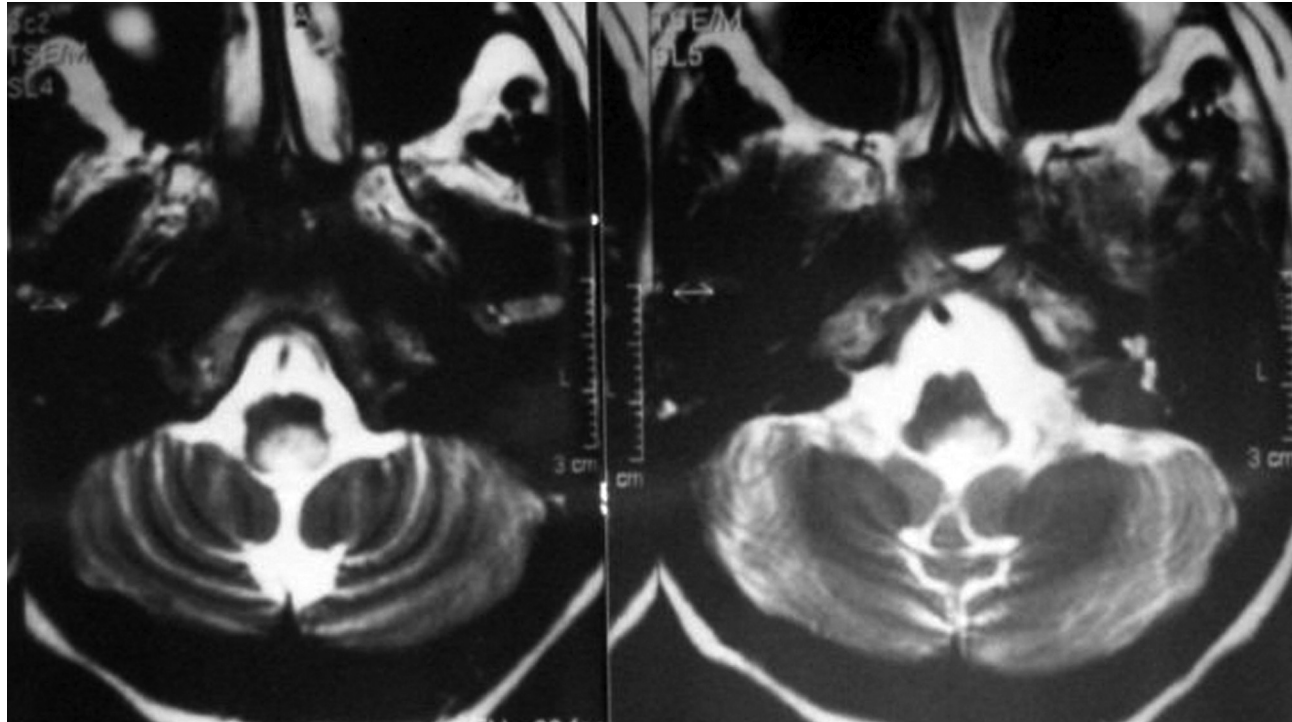


Figure 1. The T2-weighted axial magnetic resonance images show an area of hyperintensity in the medulla oblongata.

Address for correspondence: Erdem TÜZÜN
Department of Neurology, İstanbul University
İstanbul Faculty of Medicine, 34390 Çapa, İstanbul, Turkey
Phone: + 90 212 414 20 00/ ext: 32580 • Fax: + 90 212 533 43 93
E-mail: drerdem@yahoo.com

Manuscript received: 18.08.2011 **Accepted:** 28.11.2011

Turk J Gastroenterol 2012; 23 (6): 804-831
doi: 10.4318/tjg.2012.0437

mg/dl) and normal glucose concentration and oligoclonal bands. Visual evoked potentials and a comprehensive screening for infectious and systemic autoimmune disorders were normal. Intravenous (i.v.) 1000 mg methylprednisolone treatment was administered for five days, and her dysphagia resolved in two weeks. In the following 14 years, she developed three transverse myelitis attacks. Aqp-4 Ab was detected in the archived sera obtained during the brainstem and myelitis attacks using a cell-based assay with Aqp-4-transfected HEK-293 cells (1).

Isolated dysphagia is a rare type of presentation for most neurological diseases. Dysphagia has been reported in a few NMO patients in association with

other symptoms (4,5). Hiccups, nausea and vomiting presumably occur due to the involvement of the area postrema, located in the dorsal medulla. The solitary tract and dorsal vagal nuclei are located in close proximity to the area postrema. However, involvement of these nuclei alone apparently does not cause dysphagia (2). Dysphagia is expected to occur due to the involvement of the nucleus ambiguus, which is far more ventrally located and is thus spared in most cases. Our patient's findings show that medulla lesions due to NMO are not necessarily confined to the dorsal medulla and might extend ventrally, causing dysphagia. NMO should thus be suspected in patients presenting with dysphagia or other ventral medulla symptoms.

REFERENCES

1. Waters P, Jarius S, Littleton E, et al. Aquaporin-4 antibodies in neuromyelitis optica and longitudinally extensive transverse myelitis. *Arch Neurol* 2008; 65: 913-9.
2. Apiwattanakul M, Popescu BF, Matiello M, et al. Intractable vomiting as the initial presentation of neuromyelitis optica. *Ann Neurol* 2010; 68: 757-61.
3. Riphagen J, Modderman P, Verrips A. Hiccups, nausea, and vomiting: water channels under attack! *Lancet* 2010; 375: 954.
4. Kobayashi Z, Tsuchiya K, Uchiyama T, et al. Intractable hiccup caused by medulla oblongata lesions: a study of an autopsy patient with possible neuromyelitis optica. *J Neurol Sci* 2009; 285: 241-5.
5. Lotze TE, Northrop JL, Hutton GJ, et al. Spectrum of pediatric neuromyelitis optica. *Pediatrics* 2008; 122: e1039-47.

Recai TÜRKOĞLU², Aşlı KIYAT-ATAMER³,
Erdem TÜZÜN¹, Gülşen AKMAN-DEMİR³

Department of ¹Neurology, İstanbul Faculty of Medicine, İstanbul

Department of ²Neurology, Haydarpaşa Numune Education and Research Hospital, İstanbul

Department of ³Neurology, İstanbul Bilim University, İstanbul

The prevalence of CYP2C19 mutations in Turkish patients with dyspepsia and influence on *H. pylori* eradication therapy

Dispeptik Türk hastalarda CYP2C19 mutasyonlarının prevalansı ve bunun H. pylori eradikasyon tedavisine etkisi

To the Editor,

We read with great interest the paper by Ozdil et al. published in your journal entitled "Influence of CYP2C19 functional polymorphism on Helicobacter pylori eradication" (1). In that paper, they re-

ported that cytochrome P450 2C19 (CYP2C19) polymorphism has an impact on *H. pylori* eradication, and heterozygous CYP2C19 extensive metabolizers (hetero EMs) had statistically signifi-

Address for correspondence: Altay ÇELEBİ

Kocaeli University School of Medicine, Department of Gastroenterology, Kocaeli, Turkey

Phone: + 90 262 303 75 29

E-mail: altaycelebi@yahoo.com

Manuscript received: 21.06.2011 Accepted: 10.07.2011

doi: 10.4318/tjg.2012.0405