

Treating TNBS-Induced colitis in rats with probiotics

Wan Yue-MENG¹, Zhu You-QING², Xia BING², Luo JUN²

Department of ¹Liver, Pancreas and Gallbladder Disease, The 2nd Affiliated Hospital of Kunming Medical College, Kunming City, China

Department of ²Gastroenterology, Zhongnan Hospital of Wuhan University, Wuhan City, China

Background/aims: We aimed to investigate the therapeutic effects of Peifeikang, a probiotics compound, on colitis in rats induced by trinitrobenzene sulfonic acid and to elucidate its potential mechanism. **Material and Methods:** We evaluated the therapeutic effects of Peifeikang by analysis of the disease activity index, colonic mucosa damage index, and histopathological score of the inflamed colons, by measurement of colonic myeloperoxidase activity through spectrophotometric assay, by determination of colonic positivities of tumor necrosis factor-alpha and interleukin-10 via immunochemical staining, and by detection of serum levels of tumor necrosis factor-alpha and interleukin-10 with enzyme-linked immunosorbent assay. **Results:** Intrarectal administration of trinitrobenzene sulfonic acid caused colonic inflammation similar to human ulcerative colitis with significantly increased disease activity index, colonic mucosa damage index, histopathological score, and colonic myeloperoxidase activities ($p < 0.05$). After treatment with Peifeikang or olsalazine alone, or both, disease activity index, colonic mucosa damage index, histopathological score, and colonic myeloperoxidase activities decreased significantly ($p < 0.05$). The relief of trinitrobenzene sulfonic acid-induced colitis was accompanied by significantly decreased production of tumor necrosis factor-alpha in both serum and intra-colon ($p < 0.05$) and by significantly increased production of interleukin-10 in both serum and intra-colon ($p < 0.05$). **Conclusions:** Peifeikang can effectively ameliorate trinitrobenzene sulfonic acid-induced colitis in rats, the underlying mechanism of which may be attributed to the modulatory effects of Peifeikang on the production of tumor necrosis factor-alpha and interleukin-10.

Key words: Probiotic, ulcerative colitis, trinitrobenzene sulfonic acid, myeloperoxidase, tumor necrosis factor-alpha, interleukin-10

Ratlarda TNBS ile oluşturulan kolitin probiyotikler ile tedavisi

Amaç: Bu çalışmada ratlarda trinitrobenzen sulfonik asit ile oluşturulan kolitte, probiyotik olan Peifeikang'ın terapötik etkisini araştırmayı ve etkisinin potansiyel mekanizmasını aydınlatmayı amaçladık. **Yöntem:** Peifeikang'ın terapötik etkinliği, hastalık aktivitesi indeksi, kolon mukozası hasar indeksi ve inflame kolon mukozasında spektrofotometrik yöntemle ölçülen kolonik myeloperoksidaz aktivitesi ile elde edilen histopatolojik skor, immunhistokimyasal incelemede kolonda tümör nekrozis faktörü-alfa (TNF- α) ve interlökin-10 boyanma düzeyi, serum TNF-a ve interlökin-10 düzeylerinin ölçümü (ELISA) ile değerlendirilmiştir. **Bulgular:** Trinitrobenzen sulfonik asitin intrarektal uygulanmasının insanlardaki ülseratif kolite benzer inflamasyona ve hastalık aktivitesi indeksi, kolon mukozası hasar indeksi, histopatolojik skorlaması ve myeloperoksidaz aktivitesi değerlerinde anlamlı artışa neden olduğu görüldü ($p < 0.05$). Tek başına Peifeikang veya olsalazine uygulamasının ertesinde veya kombine uygulama sonrasında, hastalık aktivitesi indeksi, kolon mukozası hasar indeksi, histopatolojik skorlaması ve kolonik myeloperoksidaz aktivitesi değerlerinde anlamlı azalma gözlemlendi ($p < 0.05$). Trinitrobenzen sulfonik asit ile indüklenen kolitin iyileşmesine serumda ve kolon dokusunda TNF-a düzeylerinde anlamlı azalma ve interlökin-10 düzeylerinde anlamlı artış eşlik etmekteydi ($p < 0.05$). **Sonuç:** Peifeikang trinitrobenzen sulfonik asit ile indüklenen koliti anlamlı düzeyde iyileştirebilmektedir ve altta yatan etki mekanizması TNF-a ve interlökin-10 üretimine olan etkisi ile ilişkili olabilir.

Anahtar kelimeler: Probiyotik, ülseratif kolit, trinitrobenzen sulfonik asit, myeloperoksidaz, tümör nekroze edici faktör-alfa, interlökin-10

INTRODUCTION

Both tumor necrosis factor-alpha (TNF- α) and interleukin-10 (IL-10) are pleiotropic cytokines that play a very important role in the initiation and

maintenance of inflammatory and immune response. TNF- α is widely believed to be pivotal in the development of intestinal inflammation in inf-

Address for correspondence: Zhu You-QING,
Zhongnanhospital of Wuhan University,
Department of Gastroenterology, Wuhan City, China
E-mail: Uqing zhu@yahoo.com.cn

Manuscript received: 17.09.2010 **Accepted:** 16.12.2010

Turk J Gastroenterol 2011; 22 (5): 486-493
doi: 10.4318/tjg.2011.0247

lammatory bowel disease (IBD) after the solid success of therapeutic strategies to antagonize this molecule in Crohn's disease (CD) (1,2) and ulcerative colitis (UC) (3). IL-10 is generally regarded as a very important immunoregulatory and anti-inflammatory cytokine, which exerts its anti-inflammatory effects by suppressing the production of inflammatory proteins, including TNF- α . In fact, IL-10's anti-inflammatory effect is strongly supported by the development of spontaneous enterocolitis with characteristics of IBD in IL-10-deficient mice (4) and its benefits in treating models of induced colitis (5,6). Probiotics is defined as live microorganisms which, when administered in adequate amounts, confer a health benefit on the host. To date, such different probiotic strains as bifidobacteria, lactobacilli, streptococci, *Escherichia coli*, clostridia, and also yeast have been reported to be efficient (7-9). Furrie et al. (10) reported for the first time that the combination of probiotic strain *Bifidobacterium longum* and fructooligosaccharides (FOS) conferred therapeutic benefits in the distal colon of patients with acute UC. In China, Peifeikang (PFK) is a generally available probiotic product that contains *B. longum*, *Lactobacillus acidophilus* and *Enterococcus faecalis*. One study published previously in ZhongHuaXiaoHuaZaZhi, one of China's most authoritative journals, suggested its efficacy in treating trinitrobenzene sulfonic acid (TNBS)-induced colitis in rats (11). After refining the study design, we report our study of the therapeutic effects of PFK on TNBS-induced colitis of rats with a two-fold purpose: to confirm PFK's efficacy on experimental colitis and to elucidate its potential mechanism, particularly its association with such inflammatory cytokines as TNF- α and IL-10.

MATERIALS AND METHODS

Experimental Animals

Fifty female adult Sprague-Dawley rats weighing 195 ± 20 g were purchased from the Experimental Animal Research Center of ZhongNan Hospital, Wuhan University. All the rats were housed in air-conditioned animal room at $25 \pm 2^\circ\text{C}$ and 60% humidity and exposed to 12-hour (h) light and dark cycle with free access to food and water that were refreshed everyday. The research was approved by the Institutional Review Board (IRB) of Zhongnan Hospital of Wuhan University, and the treatment of animals was according to the principles of laboratory animal care.

Experimental Groups

The rats were randomly divided into 5 groups (n=10 each) as described below:

A: Healthy control group, received 25% aqueous ethanol once at a dose of 1.0 ml/rat into the colon and intragastric medical saline at a dose of 2.0 ml/rat/day for 2 weeks.

B: Untreated TNBS-induced colitis control group, receiving intragastrically medical saline at a dose of 2.0 ml/rat/day for 2 weeks.

C: TNBS-induced colitis treated with PFK intragastrically at a dose of 0.63 g/rat/day for 2 weeks.

D: TNBS-induced colitis treated with olsalazine intragastrically at a dose of 125 mg/kg body weight for 2 weeks.

E: TNBS-induced colitis treated with both PFK and olsalazine intragastrically at the same dosage and duration as above.

Reagents and Drugs

TNBS was purchased from Sigma-Aldrich Chemical Co. Myeloperoxidase (MPO) reagent kit was supplied by JianCheng Co. (Nanjing, China). Both TNF- α and IL-10 ELISA kit for rats were from Neobioscience (Beijing, China). Olsalazine was bought from LiSheng Co. (Tianjin, China), while PFK was from XinYu Co. (Shanghai, China). ChemMateTMEnVision+HRP/DAB Rb & Mo was from BaiLi Co. (Shanghai, China) and UltrasensitiveTM S-P kit was from FuZhouMaiXin Co. (Shanghai, China), while rabbit anti-TNF- α monoclonal antibody to rat was from ZhongShanJinQiao Co. (Beijing, China) and rabbit anti-IL-10 monoclonal antibody to rat was from BoShiDe Co. (Wuhan, China).

Induction of Colitis

Ulcerative colitis (UC) was induced according to the method of Siddiqui et al. (12). Briefly, before induction of colitis, rats were starved for 24 h but had free access to water. The rats were lightly anesthetized with ether. A rubber catheter (OD, 2 mm) was inserted rectally into the colon with the tip approximately 8 cm proximal to the anus. TNBS (dissolved in 1.0 ml 50% ethanol) was instilled into the colon of rats in Groups B, C, D, and E at a dose of 25 mg/rat, while rats in Group A received only 1.0 ml 25% ethanol. After the induction of colitis, all rats were observed closely and characteristics of stool and body weight of each rat were recorded to assess the disease activity index (DAI) according to Vowinkel et al. (13).

Preparation of the Samples

At the end of the work (2 weeks later), all rats were sacrificed, blood samples were obtained and centrifuged at 3,000 g for 5 minutes (min), and serum was stored at -70°C for spectrophotometric assay of TNF- α and IL-10 (pg/ml). The inflamed colon of rats was excised, cut open along its mesenteric border and rinsed with saline to expose the mucosal surface clearly. Colonic mucosa damage index (CMDI) was assessed as previously described by Wallace *et al.* (14) 2.0 cm of each colon was fixed in 4% polyformaldehyde and subjected to histopathologic evaluation and scoring after hematoxylin and eosin staining according to Fedorak *et al.* (15). Immunochemical staining for TNF- α and IL-10 was also performed with positivities calculated by HPIAS-2000 analytic software. The remaining colon was stored at -70°C for determination of MPO activity.

Derivation of Colonic MPO Activity and Serum Levels of TNF- α and IL-10

The activity of MPO, which is found in neutrophils, can be used for evaluating the degree of colonic inflammation. Following the instruction of the commercial reagent kit, 100 mg of the frozen colon was used and assayed spectrophotometrically for MPO activity. Serum levels of TNF- α and IL-10 were also measured according to the instruction of corresponding ELISA kits for rat.

Statistical Analysis

Normality of data was evaluated by calculating Lilliefors probabilities based on the Kolmogorov-Smirnov test. Data were expressed as mean \pm standard deviation if distributed normally, with statistical significance analyzed by one-way ANOVA or repeated-measures analysis of variance. The significance was considered at p values <0.05 . All the statistical analyses were performed with Statistical Program of Social Sciences (SPSS) for Windows, version 16.0.

RESULTS

Change in DAI of all Rats During Treatment

10–24 h after administration of TNBS, rats in Groups B, C, D, and E began to show such symptoms as obvious diarrhea, inactivity and anorexia, while there were only 4 rats with minor diarrhea in Group A. DAI of all rats differed significantly at different times (multiple comparison by “time” fac-

tor, $p=0.000$). Following treatment, DAI began to decrease in the treated groups (C, D, E) on the second day and in untreated Group B on the fourth day. DAI was also significantly different among the 5 groups (multiple comparison by “group” factor, $p=0.000$), with Group A the lowest and Group B the highest ($p=0.000$). In comparison to the untreated Group B, DAIs of treated groups C, D and E were significantly lower ($p=0.000$). Group C had significantly higher DAI ($p=0.002$) and Group D had non-significantly higher DAI ($p=0.309$), when compared to Group E (Figure 1a).

Macroscopic Rating of Colonic Mucosa Damage Index (CMDI)

Obvious hyperemia, swelling, edema, and ulceration could be seen on the colonic mucosal surface of rats in Group B, in which there were 2 rats with colonic ulcers as long as 4.0 cm. In contrast, these lesions were greatly relieved in Groups C, D and E. In comparison to Group A, the CMDI of Group B was significantly increased ($p<0.05$). However, CMDI in the treated Groups C, D and E decreased significantly ($p<0.05$), as compared to untreated Group B. The CMDI was not significantly different between treated Groups C, D and E ($p=0.120$), or between treated Groups C and E and healthy Control Group A ($p=0.405$) (Figure 1b).

Histopathologic Changes of Colons in all Rats

In untreated Group B, histopathologic assessment revealed the most severe colonic inflammation with abundant infiltrated neutrophils, lymphocytes, plasma cells, eosinophils, and histiocytes into the intestinal wall, predominantly the mucosa and submucosa, crypt distortion, or abscess (Figure 2b). Ulceration, submucosal edema, cytoplasmic mucin depletion (Figure 2c), infiltration of mucosa, submucosal granulomatosis, and thickening of intestinal wall (Figure 2d) were common in untreated Group B. Such lesions typical of UC, however, were greatly relieved in treated Groups C, D and E. When compared to the healthy Control Group A (Figure 2a), histopathologic score (HPS) of untreated Group B was pronouncedly elevated ($p<0.05$). HPSs of treated Groups C, D and E were significantly inhibited ($p<0.05$), when compared to untreated Group B. There was a non-significant difference between treated groups C and D ($p=0.786$). In comparison to either treated Group C or D, HPS of treated Group E was significantly inhibited ($p<0.05$) (Figure 1c).

Colonic MPO Activity Assay

Colonic MPO activity of untreated Group B was escalated significantly compared to that of healthy Control Group A ($p=0.000$). Treatment with PFK ($p=0.036$) or olsalazine ($p=0.000$) or both ($p=0.000$) significantly suppressed colonic MPO activity compared to untreated Group B. Treatment with both PFK and olsalazine offered a larger degree of suppression of MPO activity, when compared to treatment with either PFK ($p=0.020$) or olsalazine ($p=0.021$) alone. The difference in colonic MPO activities between treatment with PFK or olsalazine did not reach significance ($p=0.876$) (Figure 1d).

Serum Levels of TNF- α and IL-10

In untreated Group B, serum levels of both TNF- α and IL-10 were significantly increased when compared to the healthy Control Group A ($p<0.001$). When treated with PFK ($p=0.030$), olsalazine ($p=0.020$), or both ($p=0.000$), serum TNF- α levels were significantly reduced, as compared to untreated Group B. In comparison to treatment with PFK ($p=0.039$) or olsalazine ($p=0.038$) alone, treatment with both achieved even greater reduction in serum TNF- α . A non-significant difference in serum TNF- α was observed between treatment with PFK

or olsalazine ($p=1.000$) alone. However, the pattern of serum IL-10 was distinct from that of TNF- α . Following treatment with PFK ($p=0.013$), olsalazine ($p=0.000$), or both ($p=0.000$), serum IL-10 rose significantly, compared to untreated Group B. Treatment with both PFK and olsalazine achieved an even greater increase in serum IL-10, when compared to treatment with either PFK ($p=0.003$) or olsalazine ($p=0.002$) alone. There was a non-significant difference between treatment with PFK or olsalazine ($p=0.433$) alone (Figure 1e).

Colonic Expression of TNF- α and IL-10

Compared with healthy Control Group A, colonic TNF- α and IL-10 positivity in untreated Group B was significantly increased ($p=0.000$). Colonic TNF- α expression was inhibited by treatment with either PFK, olsalazine, or both, when compared to untreated Group B ($p=0.000$). In comparison to treatment with either PFK or olsalazine alone, treatment with both obtained greater inhibition in colonic TNF- α expression ($p=0.000$). There was no significant difference in colonic TNF- α expression between treatment with PFK or olsalazine ($p=0.137$) alone. However, colonic IL-10 displayed a different expression modality in treatment groups. In comparison to untreated Group B,

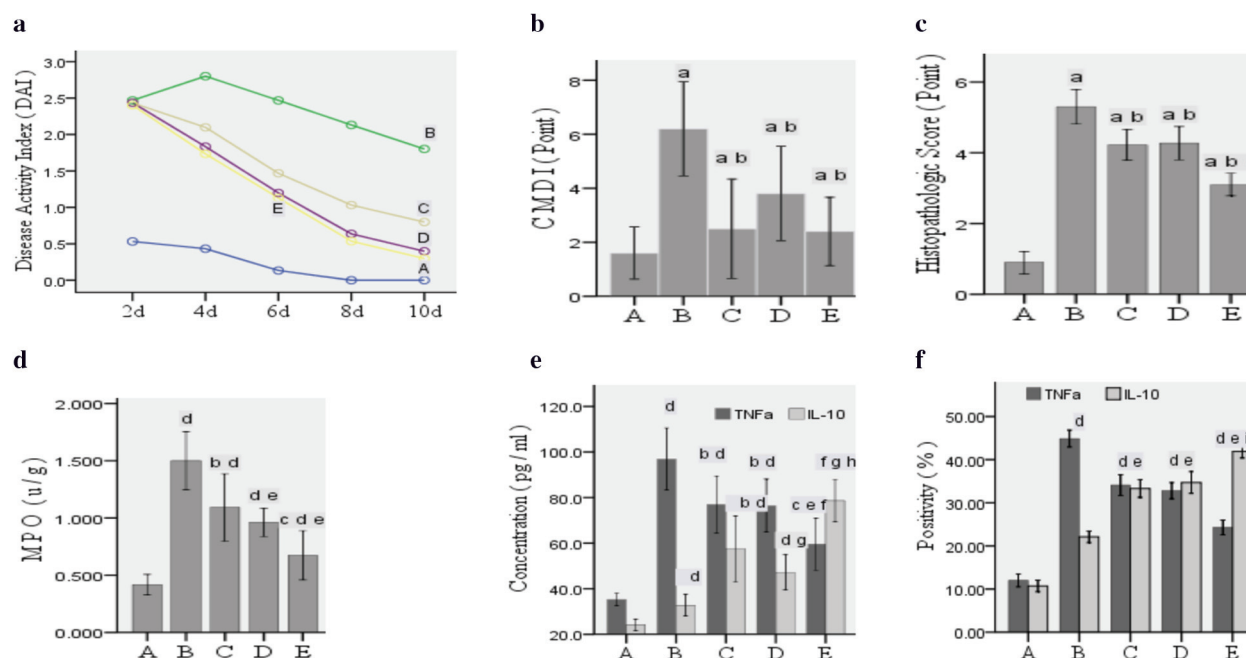


Figure 1. DAIs of all rats were analyzed by repeated-measure analysis of variance (a), while CMDI (b), HPS (c), colonic MPO (d), serum TNF- α and IL-10 (e), and colonic positivities of TNF- α and IL-10 (f) were analyzed by one-way ANOVA followed by Student-Newman-Keuls test (b, c) or Dunnett's T3 test (d, e) or LSD test (f).

^a $P<0.05$ vs. Group A, ^b $P<0.05$ vs. Group B, ^c $P<0.05$ vs. Group C or D, ^d $P<0.001$ vs. Group A, ^e $P<0.001$ vs. Group B, ^f $P<0.01$ vs. Group A, ^g $P<0.001$ vs. Group B, ^h $P<0.01$ vs. Group C or D, and ⁱ $P<0.001$ vs. Group C or D.

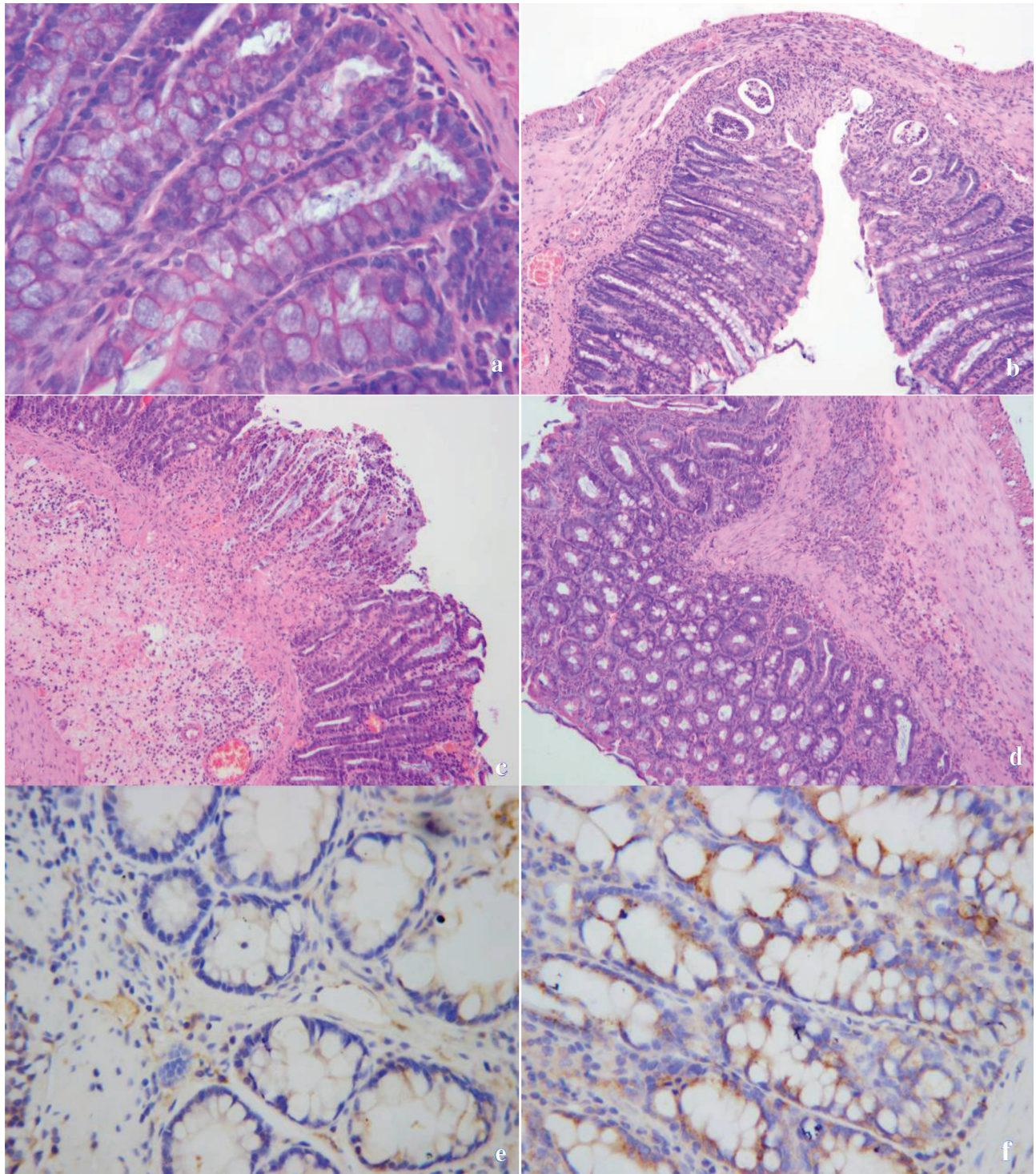
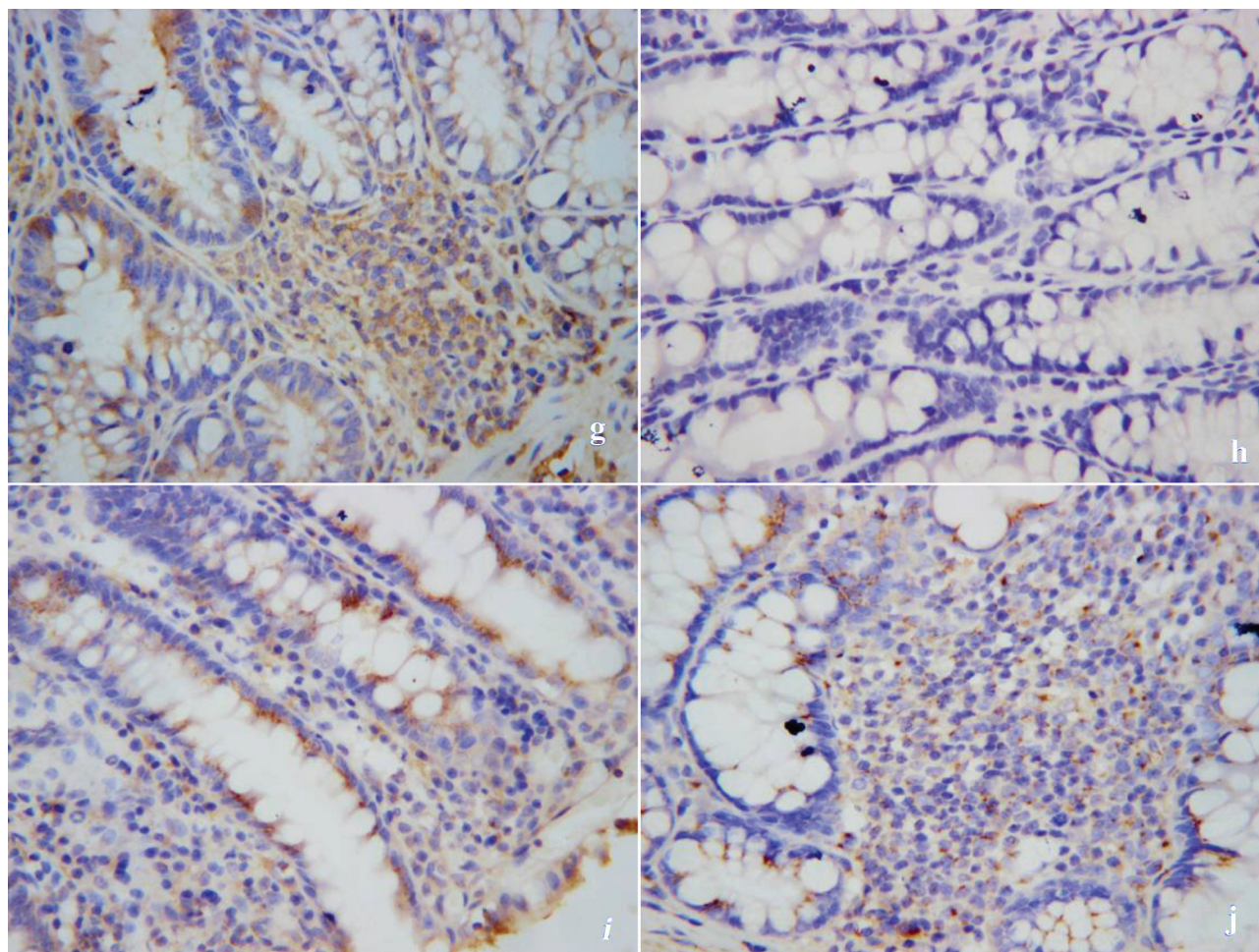


Figure 2. Hematoxylin and eosin staining for **a-d** (**a**x400, **c-d**x200): **a** healthy colon with normal colonic glands secreting abundant mucin; **b** severe colonic inflammation with 4 colonic crypt abscesses, mucosal and submucosal infiltration by polymorphonuclear leukocytes, macrophages, and lymphocytes, and nearly perforated intestinal wall; **c** colonic ulceration accompanied by submucosal hyperemia, edema, infiltration by inflammatory cells, and obviously decreased secretion of mucin by colonic glands; and **d** decreased mucin production, mucosal and submucosal infiltration by inflammatory cells, and thickening of intestinal wall with submucosal granulomatosis. Immunochemical staining for colonic TNF- α (**e-g**x400) and IL-10 (**h-j**x400): **e** healthy colon with slight production of TNF- α in mucosal epithelia and infiltrated inflammatory cells; **f** production of TNF- α primarily within mucosal epithelia; **g** production of TNF- α primarily within submucosal infiltrated inflammatory cells; **h** healthy colon with negative production of IL-10 within mucosa or submucosa; **i** production of IL-10 within both mucosal epithelia and infiltrated cells; and **j** production of IL-10 primarily within infiltrated cells.



treatment with PFK, olsalazine, or both offered significantly higher colonic expression of IL-10 ($p=0.000$). When compared to treatment with either PFK or olsalazine alone, treatment with both achieved a greater degree of IL-10 expression ($p=0.000$). Similarly, expression of IL-10 in treatment with PFK or olsalazine alone did not differ significantly ($p=0.093$) (Figure 1f).

DISCUSSION

Intrarectal administration of hapten TNBS (5~30 mg) in 0.25 ml of 50% ethanol as the "barrier breaker" can produce dose-dependent colonic ulceration and inflammation. Histologically, colonic inflammation includes mucosal and submucosal infiltration by polymorphonuclear leukocytes, macrophages, lymphocytes, connective tissue mast cells, and fibroblasts. Segmental ulceration and inflammation were common within 3 weeks after induction of colitis (16). In our study, 40 rats intrarectally given TNBS dissolved in ethanol at the dose of 25 mg/rat developed such characteristics as cli-

nic symptoms, mucosal lesions and colonic histopathologic changes similar to UC in humans.

From 10 to 24 h after the intrarectal dose of TNBS, all rats (in Groups B, C, D, E) developed diarrhea with varied severity, and 72.5% of the rats excreted bloody stool. As of the second day, clinic DAI seemed indistinguishable among these 40 rats in Groups B, C, D and E. As the treatment continued, DAI in treated Groups C, D and E decreased on the fourth day, while in untreated Group B, DAI decreased on the sixth day. This is indicative of the efficacy of treatment with PFK or olsalazine alone, or both. During the course of treatment, DAI in all groups remained in the order of $B > C > D > E > A$, with DAI in untreated Group B the highest and in Group A the lowest, which suggested firstly the efficacy of treatment with PFK or olsalazine alone, or both, and secondly the better efficacy of treatment with both PFK and olsalazine than with PFK or olsalazine alone, and the seemingly better efficacy of olsalazine than PFK.

The CMDI is assessed by taking into account the mucosa lesions of hyperemia, swelling, ulceration (number and extent of ulcers) or necrosis, which is similar to clinic endoscopic assessment of mucosal lesions. In this study, CMDI of treated Groups C, D and E were significantly lower than that of untreated Group B, which implied the better healing of inflamed mucosa in the treated than untreated groups. In treated Groups C, D and E, no significant differences in CMDI were observed, which suggested the similar effect between treatment with PFK or olsalazine alone or both in promoting mucosal healing. As a matter of fact, we also observed a non-significant difference in CMDI between treatment Groups C and E and the healthy Control Group A, which indicated a similar effect of PFK alone to PFK with olsalazine in promoting mucosal healing to normal mucosa in 2 weeks.

Histologically, treatment with PFK or olsalazine alone, or both, achieved inflammatory remission in the form of reduced HPS in Groups C, D and E compared to Group B, which suggested the anti-inflammatory effects of these treatment. HPSs in Groups C and D were not significantly different, which suggested the similar anti-inflammatory effect of PFK to olsalazine. When treated with both PFK and olsalazine, greater reduction in HPS was achieved than when treated with PFK or olsalazine alone, which suggested the synergistic effect of PFK to olsalazine in fighting colonic inflammation. The varied degrees of colonic inflammatory remission in the differently treated groups of rats were further supported by the measured colonic MPO activities. Similarly, we observed highest activity of MPO in untreated Group B, lower activity in Groups C, D and E, and lowest activity in Group A. Further, MPO activities in treated Groups C, D and E were also significantly different, with Group E significantly lower than either Group C or D, and a non-significant difference was observed between Groups C and D, which suggested the greater resolution of infiltration by neutrophils when treated with both PFK and olsalazine than with PFK or olsalazine alone.

Tumor necrosis factor (TNF)- α is a key pro-inflammatory cytokine in CD but is also found in increased concentrations in the blood, colonic tissue and stools of patients with UC (17-19). Our study conformed to these reports, in which we observed significantly increased serum level and colonic posi-

ties of TNF- α in Groups B, C, D, and E than in healthy Control Group A. However, treatment with PFK or olsalazine alone, or both, seemed to cause varying levels of decrease in serum TNF- α level and colonic TNF- α positivity, which paralleled the relief of TNBS-induced colitis.

In fact, reduced production of anti-inflammatory cytokine IL-10 is a key feature of IBD (20,21). Daily systemic administration of IL-10 is able to prevent disease onset in animal models of colitis, while a single injection is therapeutic in mice with established DSS (dextran sulphate sodium)-colitis (22). In our study, IL-10 increased after induction of colitis in Groups B, C, D, and E, when compared to healthy Control Group A. This increase can be explained by the compensatory mechanism in response to markedly increased pro-inflammatory cytokine production, primarily TNF- α , in which increase in IL-10 is stimulated by TNF- α and may in turn inhibit production of TNF- α to maintain the balance of pro- and anti-inflammatory cytokines (23,24). Unlike TNF- α , IL-10 increased rather than decreased after treatment with PFK or olsalazine alone, or both, which was inversely associated with the condition of TNBS-induced colitis in the form of decreased DAI, CMDI and HPS. Treatment with both PFK and olsalazine achieved the greatest increase in IL-10 and the greatest relief of colonic inflammation. This biologic behavior of IL-10 may be attributed to PFK, which boosted the efficacy of olsalazine by promoting production of IL-10. We may even attribute the efficacy of PFK alone to the promotion of IL-10 production, which, however, still requires a rigorously designed study to confirm.

In conclusion, PFK is efficacious in treating TNBS-induced colitis, the potential mechanism of which may be attributed to the modulation of imbalance between pro- and anti-inflammatory cytokines during the formation of colonic inflammation.

Acknowledgement: We thank Professor Bing Xia for the theoretical instruction and the Research Center of Digestive Diseases and Experimental Animal Research Center of ZhongNan Hospital, Wuhan University, for supplying the required experimental facilities. We do not have conflicted interests.

REFERENCES

1. Stack WA, Mann SD, Roy AJ, et al. Randomised controlled trial of CDP571 antibody to tumour necrosis factor- α in Crohn's disease. *Lancet* 1997; 349: 521-4.
2. Targan SR, Hanauer SB, van Deventer SJH, et al. A short term study of chimeric monoclonal antibody cA2 to tumour necrosis factor α for Crohn's disease. *N Engl J Med* 1997; 337: 1029-35.
3. Rutgeerts P, Sandborn WJ, Feagan BG, et al. Infliximab for induction and maintenance therapy for ulcerative colitis. *N Engl J Med* 2005; 353: 2462-76.
4. Kuhn R, Lohler J, Rennick D, et al. Interleukin-10-deficient mice develop chronic enterocolitis. *Cell* 1993; 75: 263-74.
5. Herfarth H, Bocker U, Janardhanam R, et al. Subtherapeutic corticosteroids potentiate the ability of interleukin-10 to prevent chronic inflammation in rats. *Gastroenterology* 1998; 115: 856-65.
6. Herfarth H, Mohanty S, Rath H, et al. Interleukin-10 suppresses experimental chronic, granulomatous inflammation induced by bacterial cell wall polymers. *Gut* 1996; 39: 836-45.
7. Sartor RB. Therapeutic manipulation of the enteric microflora in inflammatory bowel diseases: antibiotics, probiotics, and prebiotics. *Gastroenterology* 2004; 126: 1620-33.
8. Ghosh S, van Heel D, Playford RJ. Probiotics in inflammatory bowel disease: is it all gut flora modulation? *Gut* 2004; 53: 620-2.
9. Araki Y, Andoh A, Takizawa J, et al. Clostridium butyricum, a probiotic derivative, suppresses dextran sulfate sodium-induced experimental colitis in rats. *Int J Mol Med* 2004; 13: 577-80.
10. Furrie E, Macfarlane S, Kennedy A, et al. Synbiotic therapy (*Bifidobacterium longum*/SynergyI) initiates resolution of inflammation in patients with active ulcerative colitis: a randomised controlled pilot trial. *Gut* 2005; 54: 542-9.
11. Chen N, You P, Liu A, et al. The influence of T regulatory cells on experimental colitis of rats after treatment by probiotics. *ZhongHuaXiaoHuaZaZhi* 2006; 26: 100-3.
12. Siddiqui A, Ancha HR, Tedesco D, et al. Antioxidant therapy with N-acetylcysteine plus mesalamine accelerates mucosa healing in a rodent model of colitis. *Dig Dis Sci* 2006; 51: 698-705.
13. Vowinkel T, Kalogeris TJ, Mori M, et al. Impact of dextran sulfate sodium load on the severity of inflammation in experimental colitis. *Dig Dis Sci* 2004; 49: 556-64.
14. Wallace JL, Keenan CM, Gale D, et al. Exacerbation of experimental colitis by nonsteroidal anti-inflammatory drugs is not related to elevated leukotriene B4 synthesis. *Gastroenterology* 1992; 102: 18-27.
15. Fedorak RN, Empey LR, MacArthur C, et al. Microstol provides a colonic mucosal protective effect during acetic acid induced colitis in rats. *Gastroenterology* 1990; 98: 615-25.
16. Morris GP, Beck PL, Herridge MS, et al. Hapten-induced model of chronic inflammation and ulceration in the rat colon. *Gastroenterology* 1989; 96: 795-803.
17. Murch SH, Lamkin VA, Savage MO, et al. Serum concentrations of tumour necrosis factor α in childhood chronic inflammatory bowel disease. *Gut* 1991; 32: 913-7.
18. Murch SH, Braegger CP, Walker-Smith JA, et al. Location of tumour necrosis factor α by immunohistochemistry in chronic inflammatory bowel disease. *Gut* 1993; 34: 1705-9.
19. Braegger CP, Nicholls S, Murch SH, et al. Tumour necrosis factor α in stool as a marker of intestinal inflammation. *Lancet* 1992; 339: 89-91.
20. Papadakis KA, Targan SR. Role of cytokines in the pathogenesis of inflammatory bowel disease. *Annu Rev Med* 2000; 51: 289-98.
21. Castro-Santos P, Suarez A, Lopez-Rivas L, et al. TNF α and IL-10 gene polymorphisms in inflammatory bowel disease. Association of -1082 AA low producer IL-10 genotype with steroid dependency. *Am J Gastroenterol* 2006; 101: 1039-47.
22. Lindsay JO, Sandison A, Cohen P, et al. IL-10 gene therapy is therapeutic for dextran sodium sulfate-induced murine colitis. *Dig Dis Sci* 2004; 49: 1327-34.
23. Li MC, He SH. IL-10 and its related cytokines for treatment of inflammatory bowel disease. *World J Gastroenterol* 2004; 10: 620-5.
24. Siegmund B, Eigler A, Moeller J, et al. Suppression of tumor necrosis factor- α production by interleukin-10 is enhanced by cAMP-elevating agents. *Eur J Pharmacol* 1997; 321: 231-9.