

Rectal carcinoid tumor with bone marrow and osteoblastic bone metastasis: A case report

Kemik iliği tutulumu ve osteoblastik kemik metastazları olan rektal karsinoid tümör:
Olgu sunumu

Metin ÖZKAN¹, Özlem ER¹, İ. Ökkeş KARAHAN², Kemal DENİZ³, Ramazan COŞKUN¹,
Can KÜÇÜK⁴, Alper YURCİ⁵, Mustafa ALTINBAŞ¹

Departments of ¹Medical Oncology, ²Radiology, ³Pathology, ⁴General Surgery, ⁵Gastroenterology, Erciyes University Medical Faculty, Kayseri

Rectal carcinoids comprise 12.6% of all carcinoid tumors and represent the third largest group of the gut carcinoids. A 64-year-old woman was diagnosed as high-grade neuroendocrine carcinoma. She had liver, bone, and bone marrow metastasis. Carcinoid syndrome was diagnosed due to diarrhea, nausea, vomiting, tachycardia, and high level of 24-hour urinary 5-hydroxyindoleacetic acid (160 mg/24 hours). No response was obtained by octreotide treatment. Rectal carcinoid tumors usually show favorable prognosis; however, poorly differentiated tumors might have unusually aggressive behavior and resistance to treatment. Bone marrow involvement might be a poor prognostic factor in carcinoid tumor as has been the case in many other tumors.

Key words: Rectal carcinoid tumor, osteoblastic bone metastasis, bone marrow metastasis

Rektal karsinoidler tüm karsinoidlerin %12,6'sını ve barsak karsinoidlerinin üçüncü en büyük grubunu oluşturmaktadır. Altmış dört yaşında kadın hastaya yüksek greydlı nöroendokrin karsinom tanısı konuldu. Hastada karaciğer, kemik ve kemik iliği metastazı vardı. Diyare, bulantı-kusma, taşikardi ve yüksek 24 saatlik 5-HIAA (160 mg/24 saat) olması nedeniyle karsinoid sendrom tanısı aldı. Rektal karsinoid tümörler genellikle iyi prognoza sahip olmakla birlikte kötü diferansiye olanları agreziv davranış ve tedaviye direnç gösterebilirler. Kemik iliği tutulumu diğer tümörlerde olduğu gibi karsinoid tümörlerde de kötü prognostik faktör olabilir.

Anahtar kelimeler: Rektal karsinoid tümör, osteoblastik kemik metastazları, kemik iliği metastazı

INTRODUCTION

Carcinoid lesions are the most common endocrine tumors and comprise approximately 50% of all neuroendocrine tumors of the gastrointestinal tract. Rectal carcinoids comprise 12.6% of all carcinoid tumors and represent the third largest group of the gut carcinoids (1). Although most carcinoids of the rectum immunohistochemically exhibit numerous amines and peptides parallel to that of normal mucosa of the rectum, presentation with clinical symptoms or the 'carcinoid syndrome' is very rare (2). Approximately 50% of the patients with rectal carcinoids are asymptomatic (3). Although metastatic spread is a common feature in colonic carcinoids, rectal carcinoids present with metastasis in only 14% of cases (4). Interestingly, bone

marrow metastasis due to rectal carcinoids has not been reported in the available literature.

We present a case of an unusually aggressive rectal carcinoid with carcinoid syndrome and liver, bone and bone marrow metastasis.

CASE REPORT

A 64-year-old woman who had abdominal pain, constipation, painful defecation and weight loss was admitted to our hospital in September 2003. Rectal examination revealed a tumor mass. On the rectosigmoidoscopic examination, an approximately 2-3 cm ulcero-vegetative mass was seen on the anterior rectal wall. She was diagnosed as

Address for correspondence: Metin ÖZKAN

Department of Medical Oncology, Erciyes University Medical Faculty,
M.K. Dedeman Oncology Hospital, 38039 Kayseri, Turkey
Phone • Fax: +90 352 437 93 48
E-mail: metino@erciyes.edu.tr

Manuscript received: 08.03.2006 **Accepted:** 19.10.2006

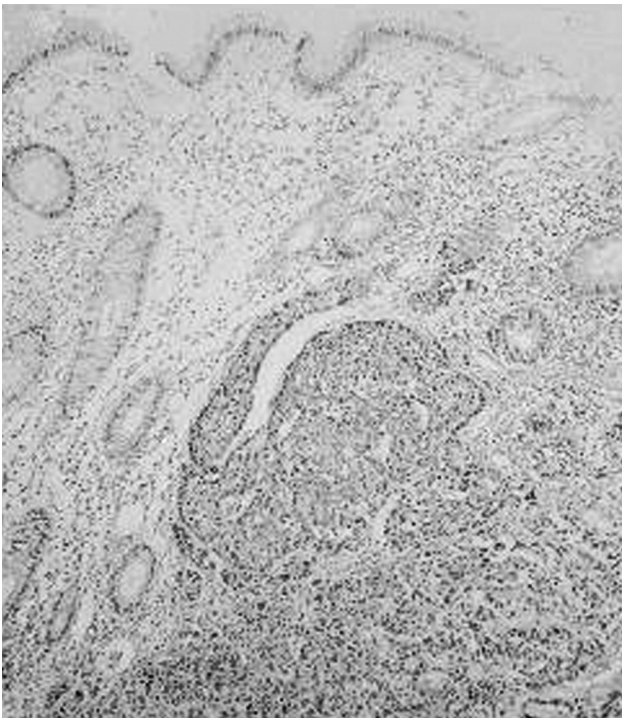


Figure 1. a) Microscopic examination showing tumor invading the mucosa (Hematoxylin & Eosin X200)

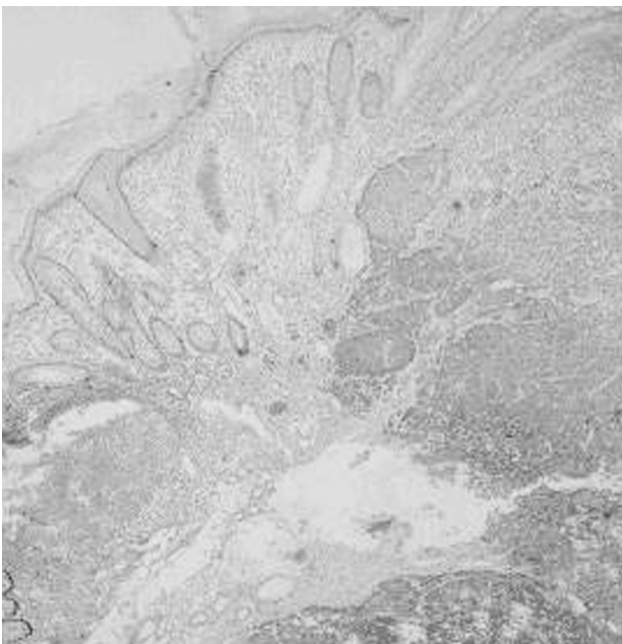


Figure 1. b) Chromogranin A positivity in tumor cells (X100)

high-grade neuroendocrine carcinoma with endoscopic biopsy. Microscopic examination showed tumor invading the mucosa and these tumor cells had chromogranin A positivity. The mitotic rate was counted as more than 10 in 10 high-power fields of light microscope (Figure 1a, 1b, 1c).

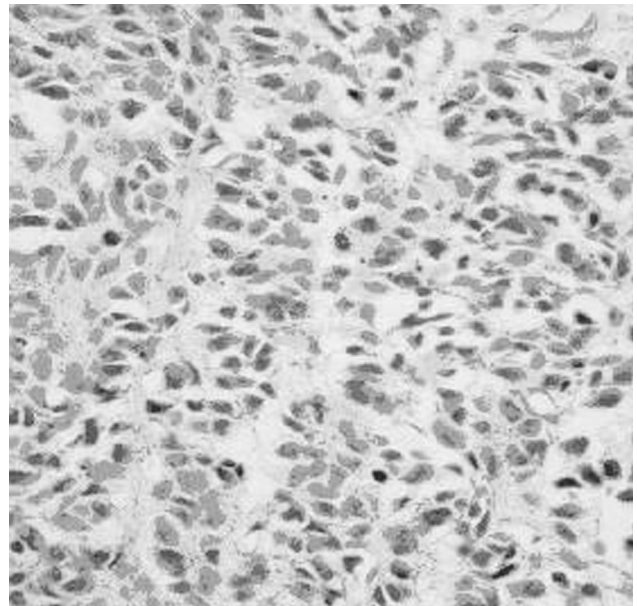


Figure 1. c) Defined nest of tumor cells separated by vascularized stroma [Note mitotic figures] (Hematoxylin & Eosin X400)

Multiple metastatic lesions were shown by abdominal ultrasonography and liver metastasis was confirmed with liver biopsy. A 24-hour urinary 5-hydroxyindoleacetic acid level of 160 mg/24 hours (normal: 2-10 mg/24 hours) supported the diagnosis of carcinoid tumor. Abdominal computerized tomography (CT) revealed multiple liver metastases and asymmetrical rectal wall thickness. In-111 octreotide scintigraphy detected accumulation at metastatic sites in the liver. We suggested radioc-chemotherapy to primary lesion and octreotide treatment, but the patient did not accept therapy. One month later, the patient again presented with difficulty at defecation and rectal pain. The case was discussed at the tumor board council and chemotherapy administration was planned. 5-FU 600 mg/m² day 1, adriamycin 50 mg/m² day 1, every 3 weeks was started. The patient had motor loss at right upper and lower extremity and back pain after two cycles of chemotherapy. Plain radiograph showed sclerotic metastasis and technetium-99m methylidiphosphonate (MDP) bone scintigraphy revealed involvement of skull, vertebra, ribs, pelvis, sternum, proximal part of bilateral femur and humerus (Figure 2). Pelvic CT examination also showed focal increased density resembling sclerotic bone metastasis at bilateral iliac bones and sacrum (Figure 3a, 3b). Radiotherapy (RT) was started for painful bone metastases. During RT, her general condition worsened, with diarrhea,

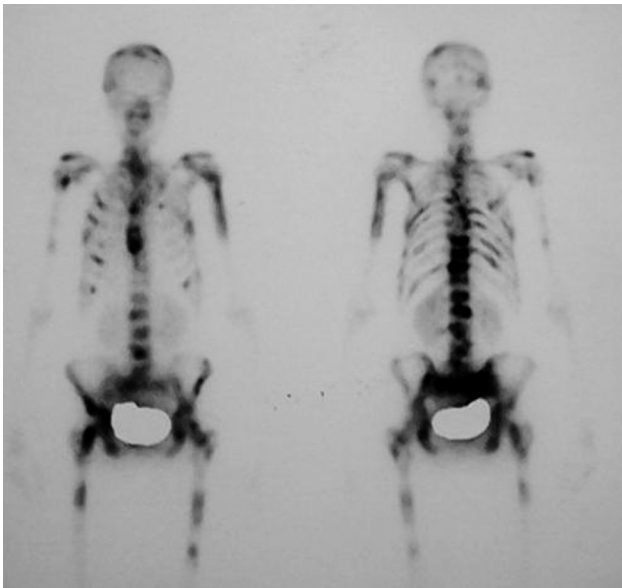


Figure 2. Technetium-99m MDP bone scintigraphy showed metastatic involvement of skull, vertebral column, bilateral femur and 1/2 proximal humerus

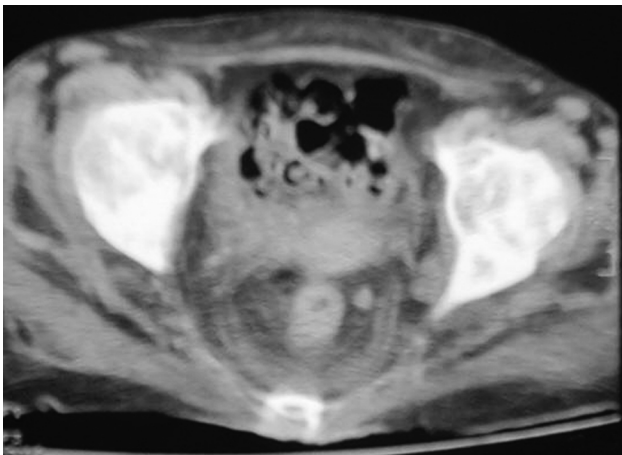


Figure 3. a) Axial CT section at the level of acetabulum showed asymmetric wall thickness resembling tumoral mass at right side of rectum. Focal increased density resembling osteoblastic metastasis of acetabulum and proximal femur was also seen

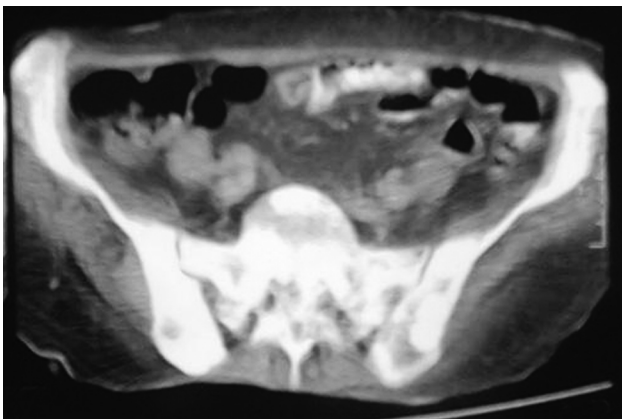


Figure 3. b) Pelvic CT examination revealed focal increased density at sacrum and bilateral iliac bones

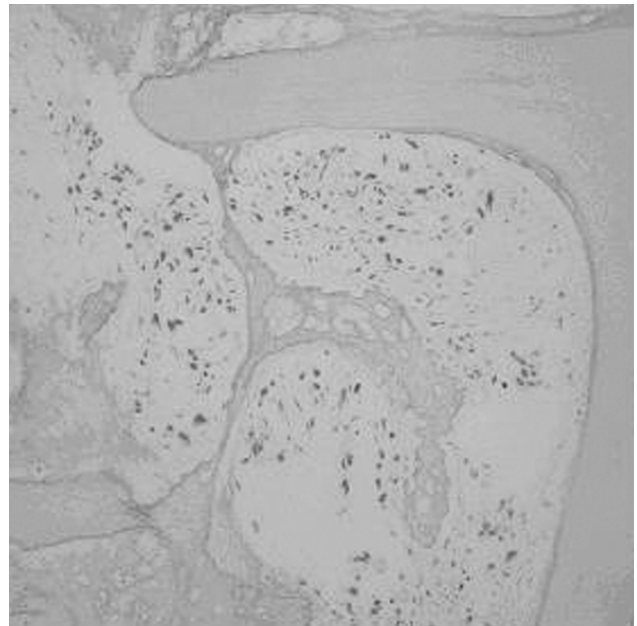


Figure 1. d) Tumor cells infiltrating bone marrow (Hematoxylin & Eosin X200)

nausea, vomiting and tachycardia developing, and she was admitted to the inpatient clinic with diagnosis of carcinoid syndrome. Electrocardiography revealed atrial fibrillation. Because of anemia (hemoglobin 9.8 g/dl, normal range for women: 12-16 g/dl), elevated alkaline phosphatase (AP) (974 U/L, normal range for women: 80-220 U/L) and elevated lactate dehydrogenase (LDH) (955 U/L, normal range 0-450 U/L), we suspected bone marrow involvement, and bone marrow biopsy was taken from anterior superior iliac crest of the pelvis. On the pathologic examination, bone marrow involvement by neuroendocrine tumor cells was detected and there was fibrosis between tumor cells and bone trabeculae (Figure 1d). A regimen of daily subcutaneous injections of octreotide 0.1 mg three times a day was initiated because of persistent diarrhea and tachycardia. Diarrhea stopped, but tachycardia continued. Symptomatic atrial fibrillation periods requiring cardioversion occurred twice. Radiotherapy to metastatic sites was completed after symptoms diminished and general condition of the patient improved. Long-lasting octreotide-LAR 1x20 mg every 3 weeks was planned and the patient was discharged home. She died 15 days after discharge.

DISCUSSION

Carcinoid tumors are neoplasms of argentaffin cells, which are characterized by the amine

precursor uptake and decarboxylation reaction. Due to their low propensity to metastasize, rectal carcinoids have a favorable prognosis with a five-year survival rate of 72%. Several parameters have been suggested as predictive criteria in the assessment of the malignant nature of these neoplasms, including tumor size, histological growth pattern, histological micro-invasiveness, presenting symptoms and DNA ploidy. Tumor size and micro-invasiveness are probably the two most important prognostic factors (1). Reports of bone metastases are infrequent in the literature. Of the primary tumors that have spread to the skeleton, most have originated in the bronchus, and only a small number from the rectum. Most often, skeletal metastases are osteoblastic lesion on roentgenograms (5, 6). Bone marrow metastasis of carcinoid tumor has rarely been observed. Oo *et al.* (7) reported carcinoid tumor, of unknown origin, presenting with bone marrow metastasis. Few rectal carcinoid cases with diffuse hematogenous metastases have been reported. Cueto *et al.* (8) reported a patient with a 4 cm rectal carcinoid with metastasis to liver, pituitary gland, spleen, lungs, and pancreas. Lertprasertsuke *et al.* (9) presented a

patient with metastasis to thyroid, pancreas, liver, kidney, bones and lymph nodes. Our patient presented with rectal mass and liver, bone and bone marrow metastasis. Bone metastasis showed osteoblastic characteristics radiologically. Tumor was poorly differentiated and did not respond to octreotide treatment.

We confirmed that there was a significant difference between hemoglobin, white blood count, platelet, LDH, AP and uric acid of the patients with and without bone marrow involvement in small cell lung cancer. Among the biochemical parameters, the elevated LDH and AP had the highest sensitivity and specificity as indicators of bone marrow invasion (10). According to this knowledge we suspected bone marrow invasion of the tumor in our patient because of anemia and elevated serum LDH and AP levels, and bone marrow biopsy revealed neuroendocrine tumor cells.

Rectal carcinoids tumors usually show favorable prognosis; however, poorly differentiated tumors might have unusually aggressive behavior and resistance to treatment. Bone marrow involvement might be a poor prognostic factor in carcinoid tumor as has been the case in many other tumors.

REFERENCES

1. Lauffer JM, Zhang T, Modlin IM. Review article: current status of gastrointestinal carcinoids. *Aliment Pharmacol Ther* 1999; 13: 271-87.
2. Mani S, Modlin IM, Ballantyne G, *et al.* Carcinoids of rectum. *J Am Coll Surg* 1994; 179: 231-48.
3. Jetmore AB, Ray JE, Gathright JB, *et al.* Rectal carcinoids: the most frequent carcinoid tumor. *Dis Colon Rectum* 1992; 35: 717-25.
4. Modlin IM, Sandor A. An analysis of 8305 cases of carcinoid tumors. *Cancer* 1997; 79: 813-29.
5. Jolles PR. Rectal carcinoid metastatic to the skeleton. Scintigraphic and radiographic correlation. *Clin Nucl Med* 1994; 19: 108-11.
6. Ladam V, Pluot M, Zeitoun P, *et al.* Rectal carcinoid tumor with osteoblastic bone metastases. Diagnostic contribution of ultrastructural studies. *Gastroenterol Clin Biol* 1980; 4: 464-8.
7. Oo TH, Aish LS, Schneider D, Hassoun H. Carcinoid tumor presenting with bone marrow metastases. *J Clin Oncol* 2003; 21: 2995-6.
8. Cueto J, Salisbury RS, Chamberlain CR, Heiskell EF. Unusually aggressive behavior of a carcinoid of the rectum (case report). *W V Med J* 1968; 64: 138-41.
9. Lertprasertsuke N, Kakudo K, Satoh S, *et al.* Rectal carcinoid tumor metastasizing to the thyroid and pancreas: an autopsy case exploiting immunohistochemistry for differentiation from tumors involving multiple endocrine organs. *Acta Pathol Jpn* 1990; 40: 352-60.
10. Ozkan M, Eser B, Er O, *et al.* Bone marrow involvement in small cell lung cancer: prognostic significance and correlation with hematological and biochemical parameters. *Asia Pac J Clin Oncol* 2006; 2: 32-8.