

A rare tumor located in the anorectal junction: Sarcomatoid carcinoma

Anorektal bileşke yerleşimli nadir bir tümör: Sarkomatoid karsinoma

Ersin ÖZTÜRK¹, Tuncaç YILMAZLAR¹, Ömer YERCİ²

Departments of ¹General Surgery and ²Pathology, Uludağ University School of Medicine, Bursa

Sarcomatoid carcinoma is a very rare tumor. Though it has been more than a century since sarcomatoid carcinoma was first described by Virchow, many unresolved points remain. Histogenesis and nomenclature are controversial. A proper management has not been defined. Patients suffering from this aggressive tumor have a very poor prognosis. However, in this paper a case with a disease-free survival of more than five years is reported.

Key words: Sarcomatoid carcinoma, anorectal, carcinosarcoma

Sarkomatoid karsinom çok nadir bir tümördür. Virchow tarafından tariflendiğinden beri bir yüzyıldan fazla olmasına rağmen halen daha çözülmemiş birçok noktası vardır. Histiyojenizi ve dolayısıyla isimlendirilmesi tartışmalıdır. Bu agresif tümörü olan hastalar kötü bir prognoza sahiptirler. Ancak bu yazıda 5 yıldan daha fazla hastaliksız yaşamı olan bir olgu sunulmuştur.

Anahtar kelimeler: Sarkomatoid karsinoma, anorektal, carcinosarkoma

INTRODUCTION

Sarcomatoid carcinoma (SC) or carcinosarcoma is a rare tumor with a poor prognosis. SC has a complex histogenesis that has been a matter of debate for over 100 years, and is now classified within spindle cell lesions (1, 2). Gastrointestinal, particularly distal, location is very rarely seen (2-5). Despite its century-long history, only two cases of SCs located in the anal canal have been reported (3). Surgical management is no different from any other malignancy surgeries. Adjuvant therapy plays no role in treatment (4). Neither treatment methods nor any other factors affect survival for alimentary tract SCs (4, 5). In this case, a patient with SC of the anorectal junction, with a disease-free survival period of more than five years, is reported, and related literature is reviewed.

CASE REPORT

A 65-year-old white female was admitted to Uludağ University School of Medicine, General Surgery Department, because of rectal bleeding occurring for the last three months. There was no

history of abdominal pain, constipation or weight loss. Digital examination revealed a mass in finger distance and a puncture biopsy was performed. Pathological examination confirmed a malignant tumor. There was no family history of any malignancy or any other predisposing factor for malignancy. Abdominal computed tomography (CT) scan showed a polypoid mass originating from the posterior wall of the distal rectum and a hypodense lesion in the liver, which was later found to be a benign lesion by perioperative biopsy. Other intra-abdominal organ systems, including genitourinary system, were all normal. The patient underwent an abdominoperineal resection for distal rectum carcinoma as the lesion was just above the dentate line. Postoperative course was normal and the patient was discharged from the hospital on the fifth day of operation.

Macroscopic pathological examination revealed a 2 x 1.5 cm polypoid gray-brown tumorous mass, 2.2 cm distant from anal verge, in a 30 cm distal colon portion.

Address for correspondence: Ersin ÖZTÜRK
Department of General Surgery, Uludağ University,
School of Medicine, Görükle 16069 Bursa, Turkey
Phone: +90 224 442 84 00/1014 • Fax: +90 224 442 83 98
E-mail: tunyil@uludag.edu.tr

Manuscript received: 08.03.2005 **Accepted:** 12.07.2006

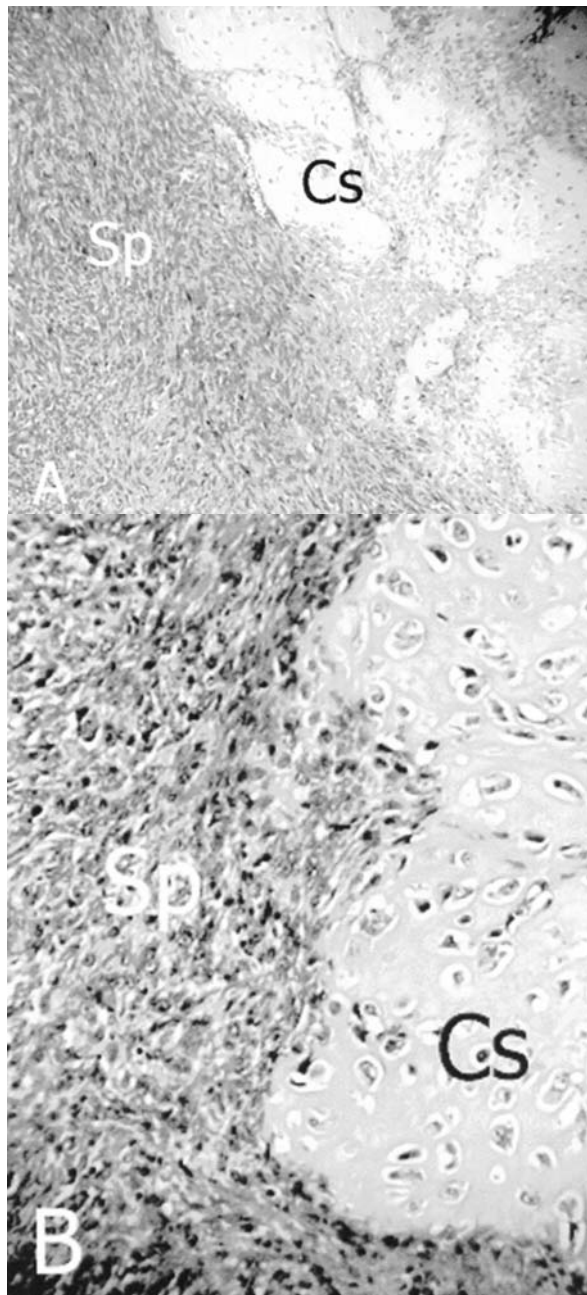


Figure 1. Chondrosarcomatous areas (Cs) and spindle cells (Sp) A) H+E x200, B) H+E x400

Microscopically, the tumor infiltrated the mucosa and submucosa of the anorectal junction. It consisted of cells that were spindle-shaped in most areas and oval-shaped in the remainder. They were large and hyperchromatic and had eosinophilic cytoplasm and some had nuclei and cells, were solid and showed diffuse distribution. Immunohis-

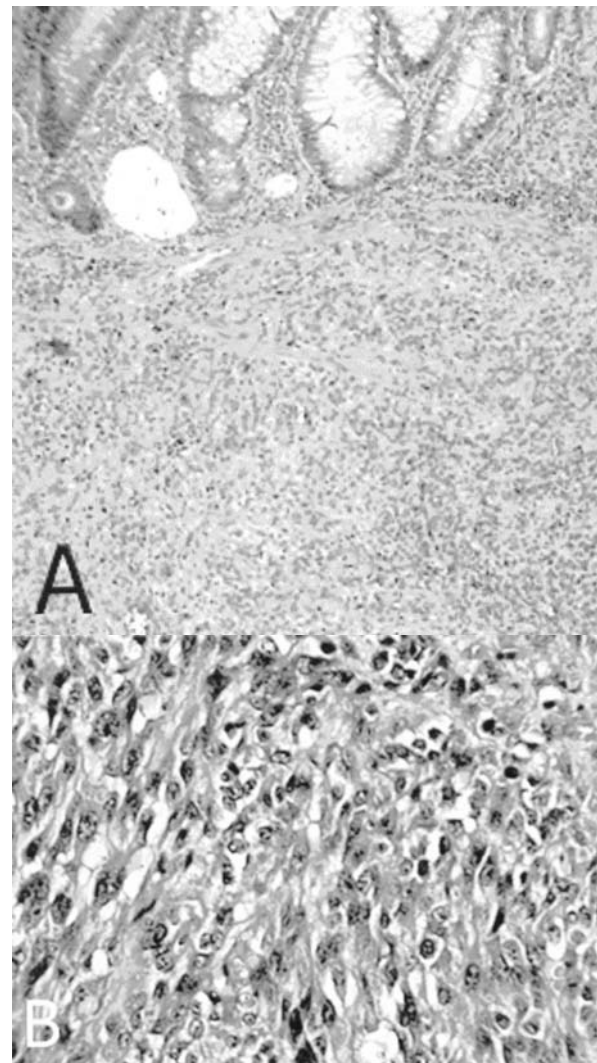


Figure 2. A) Colonic mucosa on top and spindle cells at submucosal region (H+E x100), B) Spindle cells (H+E x400)

tochemically, cells were stained by S-100 diffusely and by vimentin and cytokeratin focally and by HMB-45, SMA, Desmin, EMA, LCA, and CEA negatively. Tumor tissue contained wide chondro- and osteosarcomatoid areas (Figures 1-3).

There was no tumorous invasion in lymph nodes and the patient was accepted as having a stage 1 tumor. A curative surgery was performed with no adjuvant therapy.

On follow-up physical examination in June 2004, laboratory and imaging methods showed no sign of a recurrence. The patient has survived five post-operative years disease-free and is healthy.

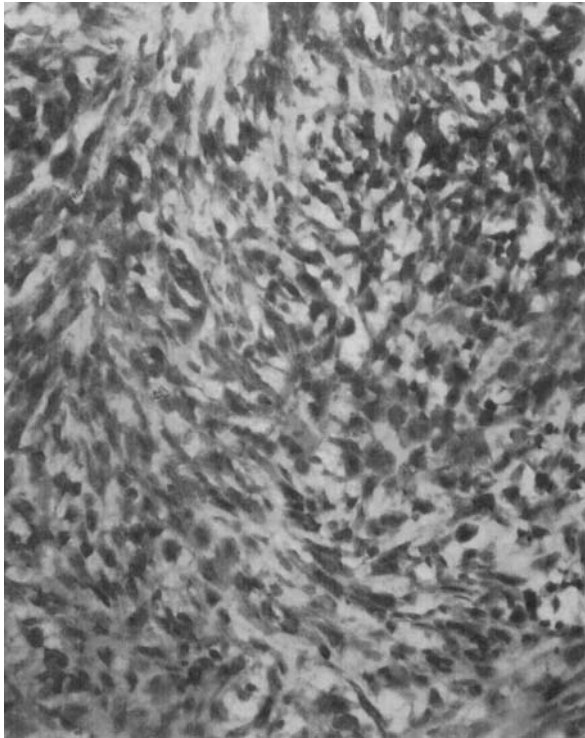


Figure 3. Cytokeratin staining

DISCUSSION

Sarcomatoid carcinomas are biphasic malignant tumors that consist of epithelial and mesenchymal tissues. It was first described by Virchow in 1864 (6). In the literature, carcinosarcoma, pseudosarcomatoid carcinoma, and spindle cell carcinoma have been used to define this lesion as well (3). It is a very aggressive tumor, which is rarely seen in the gastrointestinal system, particularly distal to the gastroesophageal junction (2-5). The more distal its localization in the distal alimentary tract the less frequently it occurs. Clinical signs are related to obstruction and/or bleeding depending on the localization (2, 4).

Sarcomatoid carcinoma accounts for up to 2% of all esophageal malignancies, whereas its incidence decreases with localization nearer to the anus (2-5). In the literature, just 10 cases of colonic (5, 7) and two anal (3) SCs have been reported. To the best of our knowledge, just one case of SC in the anorectal junction other than ours was reported, by Roncorali *et al.* (8). Liver, gallbladder, stomach, and small intestine are other sites of localization within the alimentary tract (1-3). Pancreatic SC has four well-defined subgroups: 1- spindle cell

carcinoma, 2- pleomorphic giant cell carcinoma, 3- round cell anaplastic carcinoma, and 4- malignant giant cell tumor (2, 3). Intraperitoneal localization is also reported, and the most frequent intra-abdominal site of SC is the female genital system; ovarian SC is also known as mixed Müllerian malignant tumor (1, 5, 7, 8).

Sarcomatoid carcinomas are more frequently seen in body regions other than the abdomen (1, 5, 9). Skin, lung, breast, eye, head and neck are other sites of the tumor.

There are no well-defined etiological factors that set these lesions apart from other more common malignancies that occur in the same organ systems (1).

Intestinal SCs show clinical signs in the late period and in more than 50% of the cases, symptoms of obstruction occur (4). However, our patient did not have any symptoms related to obstruction.

To date, no well-defined prognostic factors for gastrointestinal SCs have been reported (4, 5). Degree of invasion is the prognostic factor in skin and lung SCs (5). This can also be valid for abdominal SCs. In our case, the tumor was within the mucosa and submucosa. When the disease-free survival of our patient is considered, this suggestion seems to be correct.

Histogenesis of SCs is controversial (1-10). Some authors suggest that sarcomatoid and carcinoma-toid components originate from different stem cells (1, 3, 5, 9). This opinion is based on the observation that these two cell clusters are clearly separate from each other and there is no transitional zone between them (3, 9). Others have found transitional cells and common features between these cell groups and indicated that those common parts were mostly of epithelial origin. They concluded that the sarcomatoid component was also derived from epithelium (3, 5). The latter opinion has been accepted by many recently (1, 3).

Nomenclature of these malignancies has also been a matter of debate. Previously, to describe the condition in which the epithelial component was malignant and spindle cells were benign, the term "pseudosarcoma" had been used (1, 3, 9). Later, Matsusaka (10) showed that pseudosarcoma and SC were clinically and histologically the same conditions. The presence of spindle cells in the tumorous tissue is based on three basic points: it can be 1- a mesenchymal reaction to carcinoma, 2- a mixture of carcinoma and sarcoma, or 3- a

metaplastic spindle cell carcinoma. Supporters of the last opinion suggest that spindle cells are metaplastic epithelial cells, which show mesenchymal properties (10). This is supported, against some authors' claim, by the transitional zone between sarcomatoid and epithelial components (1, 3, 6, 10). Additionally, some cells expressing both carcinomatoid and sarcomatoid properties have been determined (10).

Immunohistochemical staining also affects the nomenclature. If stromal and epithelial cells express the epithelial marker cytokeratin and are stained by associated immunohistochemical stains, then the tumor is termed "sarcomatoid carcinoma", but if stromal cells do not express epithelial markers, the term "carcinosarcoma" is preferred (3, 7). However, some technical problems in staining may cause misdiagnosis. Negative staining for keratin excludes neither the presence of epithelial component nor epithelial marker expression of stromal cells (10). Multiple staining from various sites may prevent misdiagnosis (10). In addition, variant forms of cytokeratin should be examined, e.g. both low and high molecular weight cytokeratin, etc. (10). In our case, as cytokeratin was positive in both epithelial and stromal cells, the case was accepted as sarcomatoid carcinoma.

Presence of keratin in spindle cells within SCs of various body parts in immunohistochemical staining supports the epithelial origin of these cells (2, 3, 9, 10). Vimentin was previously thought to

be specific for mesenchymal cells, but today it is known that many epithelial tumors express vimentin (10).

In our case, tumorous tissue consisted of neural, chondroid and osteoid differentiation. SCs may include homologous or heterologous mesenchymal elements (e.g. neural, chondroid and osteoid components, etc.) (9).

For management, the only therapy affecting survival is surgery because of early local recurrence and lymphatic and liver metastasis (4). Currently, wide excision of the organ invaded by tumorous tissue and close follow-up seem to be the best management according to the literature reports (4, 6). It is well known that chemoradiotherapy has no effect on survival (4, 6, 9). Conzo et al. (4) reported a colonic SC case. They performed intraperitoneal hyperthermic chemoperfusion on the patient, but the patient died of recurrent disease 21 months after the first operation. When our case was admitted to our department because of rectal bleeding, it was probably during the early period, and no treatment other than surgery was performed. She has completed the fifth year disease-free and is alive without any sign of the disease. To the best of our knowledge, our case is unique because of the long survival period; there is no other colorectal SC case that has lived as long as our patient. This case indicates the importance of early diagnosis and wide margin surgery for the survival of patients having SC.

REFERENCES

1. Wick MR, Swanson PE. Carcinosarcomas: current perspectives and an historical review of nosological concepts. *Semin Diagn Pathol* 1993; 10: 118-27.
2. Al-Nafussi A, Wong NACS. Intraabdominal spindle cell lesions: a review and practical aids to diagnosis. *Histopathology* 2001; 38: 387-402.
3. Iezzoni JC, Mills SE. Sarcomatoid carcinomas (carcinosarcomas) of the gastrointestinal tract: a review. *Semin Diagn Pathol* 1993; 10: 176-87.
4. Conzo G, Giordano A, Candela G, et al. Colonic carcinosarcoma. *J Gastroenterol Hepatol* 2003; 18: 748-51.
5. Weidner N, Zekan P. Carcinosarcoma of the colon. Report of a unique case with light and immunohistochemical studies. *Cancer* 1986; 58: 1126-30.
6. Bertram P, Treutner KH, Tietze L, Schumpelick V. True carcinosarcoma of the colon. *Langenbecks Arch Chir* 1997; 382: 173-4.
7. Aramendi T, Fernandez-Acenero MJ, Villanueva MC. Carcinosarcoma of the colon: report of a rare tumor. *Pathol Res Pract* 2003; 199: 345-8.
8. Isimbaldi G, Sironi M, Assi A. Report of the second case with immunohistochemical study. *Pathol Res Pract* 1996; 192: 483-7.
9. Ishida H, Ohsawa T, Nakada H, et al. Carcinosarcoma of the rectosigmoid colon: report of a case. *Surg Today* 2003; 33: 545-9.
10. Gal AA, Martin SE, Kernen JA, Patterson M. Esophageal carcinoma with prominent spindle cells. *Cancer* 1987; 60: 2244-50.