

Effects of *Momordica charantia* L. (Cucurbitaceae) on indomethacin-induced ulcer model in rats

Ratlarda indometazinle oluşturulan ülser modeline *kudret narının* etkileri

Günnur ÖZBAKİŞ DENGİZ¹, Nesrin GÜRSAN²

¹Department of Pharmacology, ²Department of Pathology, Atatürk University Medical Faculty, Erzurum

Background/aims: Fruits of *Momordica charantia* L.-cucurbitaceae have been frequently used in folk medicine for rapid healing of cutaneous lesions and peptic ulcer, especially in Western Anatolia in Turkey. **Methods:** The anti-ulcerogenic effect of the oily extract of *Momordica charantia* fruits was investigated in male Sprague-Dawley rats. Animals were separated into six groups. Distilled water (control group), famotidine (40 mg/kg), oily extracts (5 and 10 ml/kg), and vehicles (olive oil - 5 and 10 ml/kg) were given orally (gavage). Thirty minutes later indomethacin (25 mg/kg) was administered to all the groups. Six hours later, animals were killed with decapitation. For each stomach, ulcerated and total areas were measured (mm²). The ulcer indexes for each stomach and the ulcer inhibition rates for each group were calculated, after which the stomachs were evaluated pathologically (polymorphonuclear leukocytes infiltration). **Results:** Ulcer inhibition rates were as follows: famotidine -91.54%, oily extract (5 ml/kg) -53.80%, oily extract (10 ml/kg) -98.04%, vehicle (olive oil -5 ml/kg) -18.40%, and vehicle (olive oil -10 ml/kg) -88.02%. According to polymorphonuclear leukocytes infiltration, oily extract (10 ml/kg) and vehicle (10 ml/kg) had similar effects to famotidine. **Conclusions:** The olive oil extract of *M. charantia* fruit did show a protective effect macroscopically.

Key words: *Momordica charantia* L., gastric ulcer, indomethacin, rat

Amaç: Kudret Narı (*Momordica charantia* L.-cucurbitacea) Türkiye’de özellikle Ege Bölgesi’nde, halk tababetinde, cilt lezyonlarının ve peptik ülserin hızlı iyileşmesinde sıklıkla kullanılmaktadır. **Yöntem:** Kudret narı meyvelerinin zeytinyağı ekstresinin antiülserojenik etkisi, Sprague-Dawley erkek ratlarda değerlendirildi. Denekler altı gruba ayrıldı. Distile su (kontrol grubu), famotidin (40 mg/kg), yağlı ekstre (5 and 10 ml/kg), ve taşıyıcı (zeytinyağı- 5 and 10 ml/kg) ağız yoluyla verildi. 30 dakika sonra bütün gruplara indometazin (25 mg/kg) yine ağız yoluyla uygulandı. 6 saat sonra, denekler öldürüldü. Her midenin toplam ve ülser alanları (mm²) ölçüldü. Her mide için ülser indeksleri ve her grup için ülser inhibisyon oranları hesaplandı. Daha sonra mideler patolojik olarak (polimorfonükleer lökosit infiltrasyonu) değerlendirildi. **Bulgular:** Ülser inhibisyon oranları sırasıyla şöyledi: famotidin -%91,54, ekstre (5ml/kg) -%53,80, ekstre (10ml/kg) -%98,04, taşıyıcı (zeytinyağı -5ml/kg) -%18,40, ve taşıyıcı (zeytinyağı 10ml/kg) -%88,02. Polimorfonükleer lökosit infiltrasyonu sonuçlarına göre ise: ekstre (10 ml/kg) ve taşıyıcı (10 ml/kg) famotidine benzer etkiler yapmışlardır. **Sonuç:** Kudret narının yağlı ekstresi makroskopik olarak koruyucu etki sergilemiştir.

Anahtar kelimeler: Kudret narı (*Momordica charantia* L.), mide ülseri, indometazin, sıçan

INTRODUCTION

Fruits of *Momordica charantia* L.-cucurbitaceae have been frequently used in folk medicine in Turkey (especially in Western Anatolia) and in many other countries. *Momordica charantia* is known as "Kudret Nari" in Turkey (1). Its fruits are oblong-shaped, 5-15 cm long, pendulous, orange-colored when mature and green or whitish when unripe, and the pulp is blood-red or scarlet after dehiscence. The common preparation, in Turkish folk medicine, is to use the oily extract; the whole mature fruits of *M. charantia* are cut into pieces and put

inside a jar of pure oil or almond oil and left under sunshine until the seeds have melted (two or three weeks), and then they are homogenized by pressing with a hard material, i.e. spoon. This ointment is applied to cutaneous lesions for rapid healing and is used in treatment of peptic ulcer (2). This fruit has been reported as having antioxidant activity and as containing mucin, momordicine, resin, saponic glycoside, alkaloids, polysaccharide and high carotinoids (2-5).

Address for correspondence: Günnur ÖZBAKİŞ DENGİZ
Atatürk University Medical Faculty, Department of Pharmacology,
Erzurum, Turkey
Phone: +90 442 236 07 37 • Fax: +90 442 236 09 68
E-mail: gozbakis@atauni.edu.tr

Manuscript received: 19.07.2004 **Accepted:** 15.03.2005

The aim of the present study was to evaluate both macroscopically and microscopically the anti-ulcerogenic effect of the olive oil extract of *M. charantia* L. fruit against an indomethacin-induced ulcer model in the rat.

MATERIALS AND METHODS

Drugs and Chemicals

Plant material, olive oil (Sihhat® -drinkable olive oil- acidity 0.25-0.30%), famotidine (İlsan A.Ş.- Turkey) and indomethacin (Merck Sharp & Dohme) were used, and all were given orally (gavage) with a metal orogastric tube. Indomethacin and famotidine were dissolved in distilled water.

Preparation of Plant Material

M. charantia L. mature fruits were purchased from a garden in Izmir-Dikili (West Anatolia) in October 2000. The fruit was identified by the Botanical Institutes, Atatürk University, Erzurum, Turkey, where a voucher specimen is kept. 500 g cut fruits of *M. charantia* L. were added into the 500 g olive oil and refrigerated (+ 4°C). Approximately 15 days later (when completely dispersed in olive oil), the oil was filtered with a small fine sieve and centrifuged, and then only the oily part was prepared for use.

Animals

Male Sprague-Dawley rats (150-200 g) used in the study were obtained from the Animal Laboratory of the Pharmacology Department (Medical Faculty of Atatürk University-Erzurum). The animals were maintained in standard laboratory conditions. Food was withdrawn 24 h before the experiment, but the animals were allowed free access to water. Experiments were in accordance with the recommendations from the Declaration of Helsinki and the internationally accepted principles in the care and use of experimental animals.

Procedure

The anti-ulcerogenic effects of *Momordica charantia* fruits were investigated on an ulcer model produced by indomethacin (6).

Animals were separated into six groups:

Control (distilled water -5 ml/kg), famotidine (40 mg/kg), oily extract of *M. charantia* L. fruit (5 and 10 ml/kg), and vehicle (olive oil - 5 and 10 ml/kg), respectively (groups 1, 2, 3, 4, 5 and 6). Distilled water, famotidine, extracts and vehicles were given orally, and 30 min later indomethacin (25 mg/kg-per oral) was administrated to all the groups.

Six hours later, the animals were killed by decapitation. The stomachs were removed, opened along the great curvature and washed with tap water to remove gastric contents, and examined under a dissecting microscope with square-grid eyepiece to assess the formation of ulcers. For each stomach, ulcerated and total areas were measured as mm².

The ulcer indexes (UI) for each stomach were calculated using the following formula: UI = [Ulcerated area / Total stomach area] X 100, and the ulcer inhibition rates (UIR) for each group were calculated as:

$$\text{UIR (\%)} = [(\text{UI}_{\text{CONTROL}} - \text{UI}_{\text{TREATED}} / \text{UI}_{\text{CONTROL}})] \times 100.$$

Pathological Analysis

The stomachs were fixed in 10% formalin solution and routinely processed for paraffin embedding. From each sample, 4µm thick sections were obtained and stained with hematoxylin-eosin to evaluate morphological damage. Gastric damage was scored for each histological section as follows (7): score 0- no lesion; score 1- diffuse hyperemia; score 2- one or two hemorrhagic lesions or erosions; score 3- three to five hemorrhagic lesions or erosions; score 4- more than five hemorrhagic lesions or erosions; score 5- 20 to 40% of total gastric surface with hemorrhagic lesions or multiple erosions; score 6- more than 40% of total gastric surface with hemorrhagic lesions or multiple erosions. Polymorphonuclear leukocytes (PNLs) were counted in 10 separate microscopic fields (X 200) from two sections from one animal and arithmetic mean was calculated.

Analysis of Results

All values are expressed as mean ± SEM. Results were analyzed using Kruskal Wallis variance analysis, followed by Mann-Whitney U test (2-tailed). The level of significance was accepted at $p < 0.05$.

RESULTS

Oily extracts of the *M. charantia* fruit and vehicle showed protective effects on indomethacin-induced ulcer (Table 1, Figure 1). Vehicle (10 ml/kg) had a protective effect equal to that of famotidine. When each extract group was compared with its respective vehicle group, extract group (5 ml/kg) had decreased the UI in comparison to vehicle (5 ml/kg), but the difference was not significant statistically ($p > 0.05$). The 10 ml/kg extract group de-

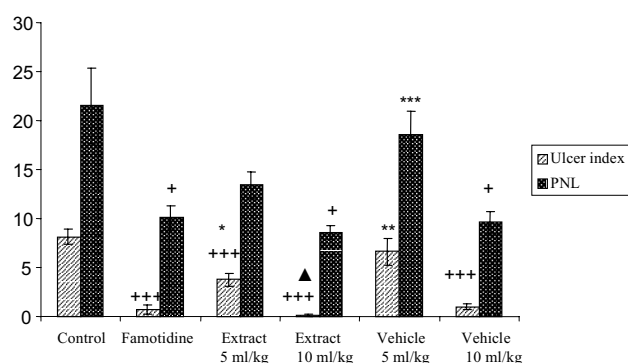
Table 1. Anti-ulcerogenic effects of olive oil extracts of *M. charantia* fruits against indomethacin-induced ulcerogenesis

Groups name	n	Ulcerated Animal	Ulcer Index (%) (Mean±SEM)	Ulcer Inhibition Rate (%)	Ulcer Score	PNL counts (Mean±SEM)
Control (only indomethacin)	8	8/8	8.122±0.798	-	6	21.5±3.851
Famotidine (40 mg/kg)	8	6/8	0.687±0.485 ⁺⁺⁺	91.54	2	10.1±1.233 ⁺
Oily extract (5 ml/kg)	8	8/8	3.752±0.698 ⁺⁺⁺	53.80	3	13.4±1.392
Oily extract (10 ml/kg)	8	2/8	0.159±0.101 ^{+++▲}	98.04	2	8.6±0.733 ⁺
Olive oil (5 ml/kg)	8	8/8	6.627±1.398 ^{**}	18.40	3	18.6±2.305 ^{***}
Olive oil (10 ml/kg)	8	8/8	0.973±0.304 ⁺⁺⁺	88.02	2	9.6±1.097 ⁺

[▲]p < 0.05: in comparison to respective vehicle groups (for the oily extract groups), ⁺p < 0.05; ^{**}p < 0.01; ⁺⁺⁺p < 0.005: in comparison to control group (only indomethacin), and ^{*}p < 0.05; ^{**}p < 0.01; ^{***}p < 0.005: in comparison to famotidine group (Mann-Whitney U test)

monstrated decreased UI in comparison to vehicle (10 ml/kg), and this decrease was significant statistically (p<0.05).

According to PNL data (Table 1, Figure 1), both the vehicle and the extracts had decreased the PNL counts, in comparison to the indomethacin group, and the extract (10 ml/kg) and vehicle (10 ml/kg) demonstrated similar effects to famotidine. Extract groups (5-10 ml/kg) decreased the PNL counts in comparison to the respective vehicle groups, but differences were not significant statistically (p>0.05).



[▲]p < 0.05: as compared to respective vehicle groups (for the oily extract groups), ⁺p < 0.05, ^{**}p < 0.01, ⁺⁺⁺p < 0.005: as compared to control group and ^{*}p < 0.05, ^{**}p < 0.01, ^{***}p < 0.005: as compared to famotidine group (Mann-Whitney U test)

Figure 1. Effects of *M. charantia* extract, vehicle and famotidine against indomethacin-induced ulcer model in rats

DISCUSSION

In our study, the oily extract and olive oil at high doses are effective against indomethacin-induced ulcer model, and the high-dose extract is more effective than famotidine. It is well known that ulcer results from an imbalance of the interactive process of aggressive and defensive factors of the

stomach. Ulcer formation induced by indomethacin is known to be related with inhibition of cyclooxygenase that prevents prostaglandin biosynthesis, which in turn inhibits the release of mucus, a defensive factor against gastrointestinal damage (8). Recruitment and activation of neutrophils in gastric mucosa are crucial in indomethacin-induced gastric injury, and it has been reported that indomethacin-induced gastric mucosal damage peaked six hours after administration (9). In our study, animals were sacrificed six hours later, and the extract (10 ml/kg), olive oil (10 ml/kg) and famotidine decreased the PNL infiltration in comparison to the control group, and this decrease was statistically significant. But, when the extract groups were compared with respective vehicles (olive oil), similar effects were observed. That is to say, the extract was not effective against indomethacin-induced PNL infiltration. Anti-ulcerogenic effects of this fruit have been examined in various experimental ulcer models, but we could not find a histopathological study of any extract of the fruit. In a previous study (10), anti-ulcerogenic activity of this fruit (various extracts) was studied using immobilization plus cold-induced stress and indomethacin-induced ulcer models in rats; material and fractions were found to be totally ineffective. The authors even claimed that olive oil itself was more effective than the oily extract of the fruit and that the fruit had a placebo effect. The reason for the difference between the study of Yıldırım (10) and our study may be that indomethacin was administered at a 30 mg/kg dose in Yıldırım's study, and at a 25 mg/kg dose in our study. In another study (5), anti-ulcerogenic activity of the olive oil extract of the fruit was studied against ethanol-induced ulcerogenesis, and a dose-dependent anti-ulcerogenic activity (94.5-97.9% inhibition) was observed. The authors had suggested that a correct model might be crucial for the activity assessment of the fruit. In our study, the extract showed

a dose-dependent anti-ulcerogenic activity (UIR= 53.80-98.04%) in comparison with the control group (only indomethacin). When the anti-ulcerogenic activities (UIR) of the extract groups versus respective control (vehicle) groups were calculated, they were 43.38% and 83.66% for the extract at 5 and 10 ml/kg doses ($p= 0.055$ and $p= 0.015$), respectively. That is to say, the anti-ulcerogenic activity of the extract at 10 ml/kg dose is statistically significant.

It has also been suggested that *M. charantia* fruit has antispasmodic and anti-cholinergic effects (11), that the fruits have antioxidant activity, with the fruit juice being a strong scavenger of superoxide and hydroxyl radicals (12), and that chloroform fraction of the fruits have shown some inhibitory activity against standard and clinical strains of *Helicobacter pylori* (13).

In non-steroidal anti-inflammatory drugs-induced gastropathy, recent studies have focused on the role of oxygen free radicals in mediating the microvascular disturbance associated with gastric mucosal injury (14), but we could not study the antioxidant activity of this fruit. In this study, the olive oil at high dose also showed the anti-ulcerogenic activity. It has been reported that olive oil includes oleic acids and that it decreases gastric acid secretion by increasing the secretin secretion (15).

In our study, although the oily extract of *M. charantia* fruit microscopically showed little anti-ulcerogenic effect versus vehicle, macroscopically it did show a protective effect at high dose. In conclusion, further investigations should be done regarding the anti-ulcerogenic activity of this fruit used in folk medicine in Turkey and in many other countries.

REFERENCES

- Yeşilada E, Sezik E, Honda G, et al. Traditional medicine in Turkey IX: folk medicine in north-west Anatolia. *J Ethnopharmacol* 1999; 64: 195-210.
- Baytop T. Türkiye'de Bitkilerle Tedavi Geçmişte ve Bugün. İstanbul: Nobel Tıp Kitabevleri, 1999; 279-80.
- Scartezzini P, Speroni E. Review on some plants of Indian traditional medicine with antioxidant activity. *J Ethnopharmacol* 2000; 71: 23-43.
- Lewis WH, Elvin-Lewis MPF. Medical botany, plants affecting man's health. New York: 1977; 35-36.
- Gürbüz I, Akyüz Ç, Yeşilada E, et al. Anti-ulcerogenic effect of *Momordica charantia* L. fruits on various ulcer models in rats. *J Ethnopharmacol* 2000; 71: 77-82.
- Süleyman H, Demirezer LÖ, Büyükkuroğlu ME, et al. Anti ulcerogenic effect of *Hippophae rhamnoides* L. *Phytother Res* 2001; 15: 625-7.
- Melchiorri D, Sewerynek E, Reiter RJ, et al. Suppressive effect of melatonin administration on ethanol-induced gastroduodenal injury in rats *in vivo*. *Br J Pharmacol* 1997; 121: 264-70.
- Bandyopadhyay SK, Pakrashi SC, Pakrashi A. The role of antioxidant activity of *Phyllanthus emblica* fruits on prevention from indomethacin-induced gastric ulcer. *J Ethnopharmacol* 2000; 70: 171-6.
- Ding SZ, Lam SK, Yuen ST, et al. Prostaglandin, tumor necrosis factor alpha and neutrophils: causative relationship in indomethacin-induced stomach injuries. *Eur J Pharmacol* 1998; 348: 257-63.
- Yıldırım OF. *Momordica charantia* L. (Kudret Narı) Bitkisinin Çeşitli Ekstrelerinin Sıçanlarda Deneysel Olarak Oluşturulan Peptik Ülserde Etkisinin İncelenmesi (Studies on the effect of *Momordica charantia* L. on the experimentally-induced peptic ulcer in rats). Yüksek Lisans Tezi (Master thesis), Gazi Univ. Sağlık Bilimleri Enstitüsü (Gazi University, Institute of Medical Sciences), 1994.
- Bever BO, Zahnd GR. Plants with oral hypoglycemic action. *Quart J Crude Drug Res* 1979; 17: 139-96.
- Sreejayan MNAR. Oxygen free radical scavenging activity of the juice of *Momordica charantia* fruit. *Fitoterapia* 1991; 62: 344-6.
- Yeşilada E, Gürbüz I, Shibata H. Screening of Turkish anti-ulcerogenic folk remedies for anti-*Helicobacter pylori* activity. *J Ethnopharmacol* 1999; 66: 289-93.
- Yoshikawa T, Naito Y, Kishi A, et al. Role of active oxygen, lipid peroxidation and antioxidants in the pathogenesis of gastric mucosal injury induced by indomethacin in rats. *Gut* 1993; 34: 732-7.
- Rhee CJ, Chang MT, Lee KY. Mechanism of oleic acid-induced inhibition on gastric acid secretion in rats. *Am Physiol Soc* 1991; 260: 564-70.