

Epiphrenic diverticulum with abnormal manometry: A case report

Anormal monometrili epifrenik divertikül: Olgu sunumu

Oğuz ÜSKÜDAR¹, Ülkü DAĞLI¹, Mehmet ASIL¹, Sinan YOL², Nurgül ŞAŞMAZ¹

Türkiye Yüksek İhtisas Hospital Department of Gastroenterology¹, Department of Gastrointestinal Surgery², Ankara

A 50-year-old man was admitted to our hospital with the chief complaints of vomiting and nocturnal cough for one year. His complaints were progressive and had worsened within the last two months. Chest X-ray revealed a right-sided paracardiac opacity. Computed tomography of the thorax showed a supradiaphragmatic mass lesion containing air and solid components. Barium esophagogram revealed a giant distal esophageal diverticulum and hiatal hernia. Stationary manometric examination of the esophagus showed non-specific esophageal motility disorder. The patient underwent a successful abdominal approach diverticulectomy operation and the postoperative course was uncomplicated. There is a high prevalence of esophageal motility abnormalities in patients with epiphrenic diverticula, though they are very rare, and, as in this case, may be difficult to classify.

Keywords: Esophagus, diverticula, epiphrenic, esophageal motility

50 yaşında bir erkek hasta 1 yıldır devam kusma ve geceleri olan öksürük şikayeti ile hastanemize başvurdu. Şikayetleri giderek artmış ve son 2 ayda daha da şiddetlenmiş. Akciğer filminde sağ parakardiyal opasite izlendi. Toraksın bilgisayarlı tomografisinde diafragma üzerinde, içerisinde hava ve katı komponentleri içeren kitle lezyonu dörüldü. Baryumlu özefagogramda distal özefagusta divertikül ve hiatal herni izlendi. Monometrik incelemede özgün olmayan özefagus motilite bozukluğu saptandı. Hastaya başarılı bir şekilde abdominal divertikülektomi uygulandı ve postoperatif dönemde sorun yaşamadı. Epifrenik divertikülü olan hastalarda özefagus motilite bozukluğu prevalansı yüksektir ancak nadiren, bu vakada olduğu gibi, bunu sınıflamak güç olabilir.

Anahtar Kelimeler: Özofagus, divertikül, epifrenik, özofagus motilitesi

INTRODUCTION

Esophageal diverticula are relatively rare pathologies. They are commonly classified according to location as pharyngoesophageal (Zenker's diverticula), midthoracic or epiphrenic diverticula (1). Epiphrenic diverticula are located in the distal 10 cm of the esophagus and comprise about 10% of all esophageal diverticula (2, 3).

The pathophysiology of the epiphrenic diverticula is not fully understood. Esophageal motility disorders, esophageal obstruction, and weakness of the esophageal wall are thought to be the underlying pathophysiological mechanisms (4).

Clinical manifestations of the epiphrenic diverticula are variable. They vary in type, severity, and frequency. Up to 80% of the patients may be asymptomatic. The most common presenting

symptoms are dysphagia and regurgitation (5). Symptoms usually progress with time.

Most of the epiphrenic diverticula are diagnosed incidentally. Chest radiograph, barium esophagogram, endoscopy, and manometry are the diagnostic tools. Asymptomatic patients should be conservatively managed. Symptomatic patients should undergo surgical treatment (6). Surgical treatment involves diverticulectomy and myotomy. There is debate about whether an antireflux procedure is needed (7).

In this case report we present a patient admitting to our hospital with the chief complaints of vomiting and nocturnal cough.

Address for correspondence: Oğuz ÜSKÜDAR
Türkiye Yüksek İhtisas Hospital Department of Gastroenterology
Sıhhiye, Ankara, Turkey
Phone: +90 312 378 86 38
E-mail: ouskudar@hotmail.com

Manuscript received: 12.12.2003 **Accepted:** 16.03.2004

CASE REPORT

A 50-year-old man was admitted to our Gastroenterology Department with the chief complaints of vomiting and nocturnal cough for one year. He stated that his complaints were progressive and had worsened within the last two months. He described his vomits as containing undigested foods that were eaten some days before. He had been admitted to another hospital two months previously and was diagnosed as achalasia and one session of balloon dilatation was performed accordingly. An esophageal manometry was not performed; the diagnosis of achalasia was based on barium esophagogram. The dilatation procedure resulted in no relief in symptoms.

Upon admission physical examination of the patient was completely normal. Laboratory findings including complete blood count, erythrocyte sedimentation rate, and biochemical tests were all within normal limits. Chest X-ray revealed a right-sided paracardiac opacity (Figure 1). Abdominal ultrasonography was normal. Computed tomography of the thorax showed a supradiaphragmatic mass lesion containing air and solid components (Figure 2). Barium esophagogram revealed a giant distal esophageal diverticulum and hiatal hernia (Figure 3). Endoscopic examination could be performed only after esophageal decompression

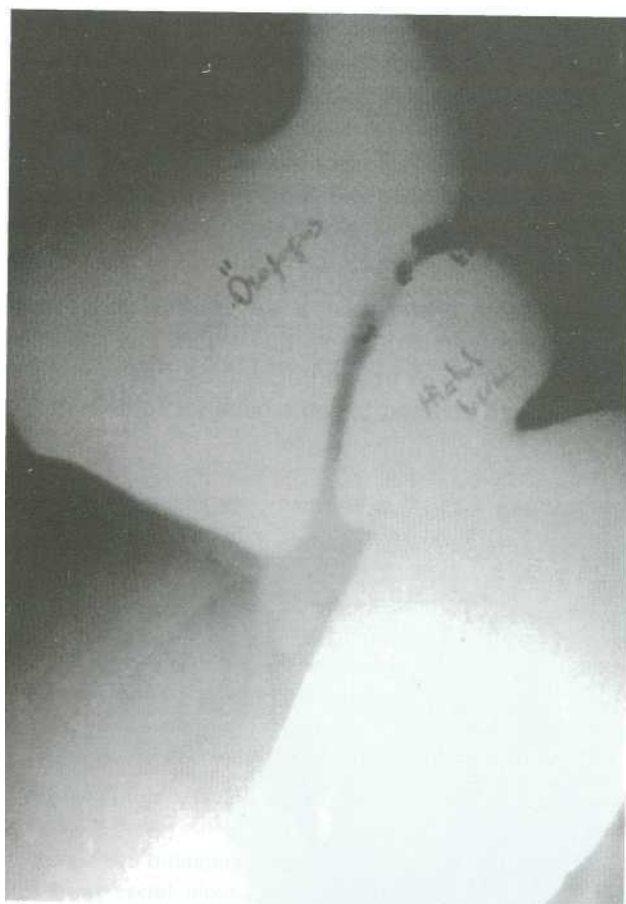

Figure 2. Barium esophagogram: A large epiphrenic diverticulum

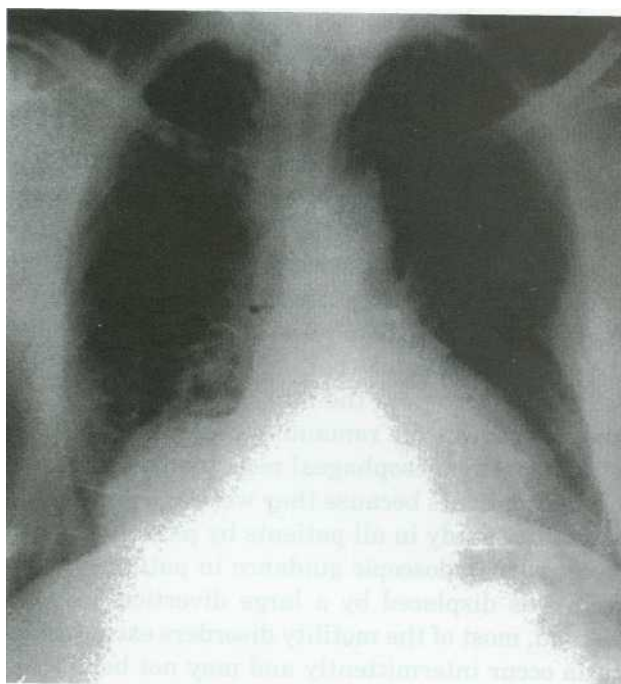


Figure 1. Chest X-ray: Right paracardiac mass lesion is seen

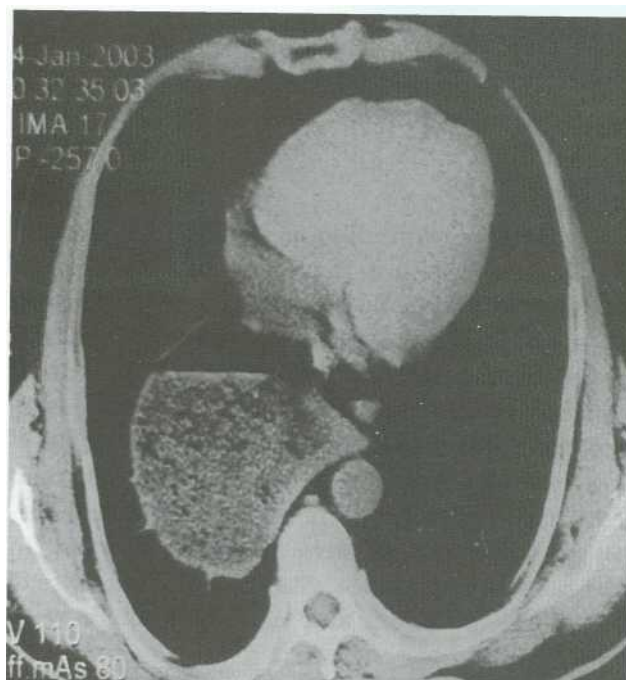


Figure 3. Computed tomography: Mass filled with solid and gas in the chest

and revealed an epiphrenic diverticulum (Figure 4). Manometry catheter was placed with the help of an endoscopy and a snare since the lower esophageal sphincter was displaced by the large diverticulum. Stationary manometric examination of the esophagus showed non-specific esophageal motility disorder with normal lower esophageal sphincter (LES) relaxation.

The patient underwent a successful abdominal approach diverticulectomy operation. The postoperative course was uncomplicated and he was discharged and advised to come back for follow-up.

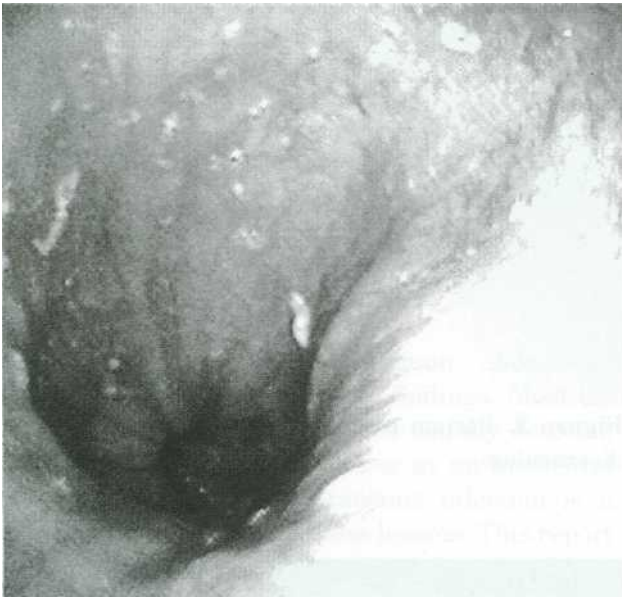


Figure 4. Endoscopic view of the diverticulum

DISCUSSION

Dysphagia, regurgitation or vomiting, chest pain, and weight loss are the common complaints of epiphrenic diverticula. However, symptoms are often non-specific and may be the result of an associated esophageal motility disorder (8). Nocturnal coughing, pneumonia, and laryngitis may develop secondary to aspiration of undigested food. Because he had a giant diverticulum, vomiting and nocturnal cough due to retention and regurgitation of undigested food were the chief complaints in our case. In accordance with the natural course of symptoms, vomiting and nocturnal cough were progressive in our patient.

Contrast radiography is the prime diagnostic tool of epiphrenic diverticula. Evaluation of the diver-

ticulum, associated esophageal abnormalities, and complications are assessed by a barium esophagogram. Esophagoscopy adds little to the evaluation of the diverticulum but may be indicated in the assessment of other esophageal abnormalities. Motility studies, which may be difficult or hazardous to perform, usually show an associated motility disorder and may influence treatment decisions (6).

Epiphrenic diverticulum is typically demonstrated in a computed tomography examination as a thin walled, air- or air-fluid filled structure communicating with the esophagus. However, those not associated with a distal esophageal obstruction (stricture, achalasia) may remain contracted in the resting state and thus may not be visible. Occasionally the diverticulum may have to be differentiated from mediastinal abscess or tumors and even hiatus hernia (9).

The pathophysiology of the epiphrenic diverticula is not fully understood. In 1833 Mondiere first suggested that pulsion forces may lead to formation of epiphrenic diverticula (5). Later in 1968 Cross proved that esophageal motility disorders were responsible for epiphrenic diverticula using esophageal manometry (10). Today epiphrenic diverticula are thought to result from esophageal motility disorders rather than primary anatomic abnormalities (8, 11). Achalasia, diffuse esophageal spasm, and non-specific esophageal motility disorders are the common motility disorders encountered with epiphrenic diverticula.

The prevalence of esophageal motility disorders in patients with epiphrenic diverticula varies between 52% and 100% in different series (8, 12, 13). There are some reasons for this inconsistency. First, the presence of a sizeable diverticulum may prevent the correct placement of the manometry catheter and therefore prevent identification of a motility disorder. Benacci *et al.* reported motility disorders in 60% of their patients because they were unable to pass the manometry catheter into the stomach in the remaining patients (8). Nehra *et al.* identified esophageal motility disorder in all of their patients because they were able to perform a motility study in all patients by passing the catheter with endoscopic guidance in patients whose LES was displaced by a large diverticulum (12). Second, most of the motility disorders except achalasia occur intermittently and may not be diagnosed during a stationary manometry, which is based on 10 swallows in the fasting state. Twenty-fo-

ur-hour ambulatory manometry is based on more than 1000 swallows and therefore may increase the diagnostic yield. In a recent study, Nehra et al. identified a motility disorder in all of 24 patients. In 23 of these patients motility disorder could be identified by a stationary manometry. But an esophageal motility disorder was diagnosed only by 24-hour ambulatory manometry in one patient (12). Therefore, 24-hour ambulatory manometry should be considered when a stationary manometry fails to identify a motility disorder. In our patient a stationary manometry was performed after placement of the manometry catheter with endoscopic guidance and non-specific esophageal motility disorder could be identified. A 24-hour ambulatory esophageal motility study yields better definition of the esophageal body function, but we were unable to perform this; therefore, we could not clarify the exact underlying motility disorder.

Hiatus hernia accompanies 33-75% of patients with esophageal diverticula. Although it was initially suggested, today there is no certain evidence that hiatus hernia has an etiological relationship with esophagus diverticula (14).

Asymptomatic patients with an epiphrenic diverticulum do not require operation. Resection or imbrication of a diverticulum is the operative method of treatment in symptomatic patients. Abdominal or transthoracic approach may be preferred. The current data support the addition of myotomy to diverticulectomy. Myotomy is contraindicated when gastroesophageal reflux exists or the LES pressure is below normal (15). The underlying motility disorder, determined by preoperative manometry, plays a crucial role in the length of the myotomy. In order to prevent postoperative reflux, a partial fundoplication can be added. Independent of location or size, surgical therapy of diverticula of the esophagus has a success rate of more than 90% (16).

In summary, epiphrenic diverticula are rare in incidence but it should be kept in mind in the differential diagnosis of space occupying lesions on chest X-ray. Although there is a high prevalence of esophageal motility abnormalities in patients with epiphrenic diverticula, as in our case, it may be difficult to clarify the underlying motility disorder with stationary monometric study.

REFERENCES

1. Baker ME, Zuccaro G Jr, Achkar E, Rice TW. Esophageal diverticula: patient assessment. *Semin Thorac Cardiovasc Surg* 1999; 11: 326-36.
2. Guerra JM, Zuñi M, Garcia I, Moreno E. Epiphrenic diverticula, esophageal carcinoma and esophagopleural fistula. *Hepato-Gastroenterol* 2001; 48: 718-9.
3. Orringer MB. Epiphrenic diverticula: fact and fable. *Ann Thorac Surg* 1993; 55: 1067-8.
4. Ferraro P, Duranceau A. Esophageal diverticula. *Chest Surg Clin N Am* 1994; 4: 741-67.
5. Thomas ML, Anthony A, Fosh BG, et al. Oesophageal diverticula. *Br J Surg* 2001; 88: 629-42.
6. Jordan PH Jr, Kinner BM. New look at epiphrenic diverticula. *World J Surg* 1999; 23: 147-52.
7. Hudspeth DA, Thorne MT, Conroy R, Pennell TC. Management of epiphrenic esophageal diverticula. A fifteen-year experience. *Am Surg* 1993; 59: 40-2.
8. Benacci JC, Deschamps C, Trastek VF, et al. Epiphrenic diverticulum: results of surgical treatment. *Ann Thorac Surg* 1993; 55: 1109-13.
9. Kim KW, Berkmen YM, Auh YH, Kazam E. Diagnosis of epiphrenic esophageal diverticulum by computed tomography. *J Comput Tomogr* 1988; 12: 25-8.
10. Cross FS. Esophageal diverticula related neuromuscular problems. *Ann Otol Rhinol Laryngol* 1968; 77: 914-26.
11. Rivkin L, Bremner CG, Bremner CH. Pathophysiology of mid-esophageal and epiphrenic diverticula of esophagus. *S Afr Med J* 1984; 66: 127-9.
12. Nehra D, Lord RV, DeMeester TR, et al. Physiologic basis for the treatment of epiphrenic diverticulum. *Ann Surg* 2002; 235: 346-54.
13. Fekete F, Vonnas C. Surgical management of esophageal thoracic diverticula. *Hepatogastroenterology* 1992; 39: 97-9.
14. Mulder DG, Rosenkranz E, DenBesten L. Management of huge epiphrenic esophageal diverticula. *Am J Surg* 1989; 157: 303-7.
15. Clark SC, Norton SA, Jeyasingham K, Ridley PD. Oesophageal epiphrenic diverticulum: an unusual presentation and review. *Ann R Coll Surg Engl* 1995; 77: 342-5.
16. Theisen J, Stein HJ, Siewert JR. Therapy of esophageal diverticula. *Ther Umsch* 2001; 58: 134-6.