

# Hypereosinophilic syndrome: Case report

## Hipereozinofilik sendrom: Olgu sunumu

Özlem YÖRÜK<sup>1</sup>, Nilüfer BULUT<sup>1</sup>, Rana ÇERİKÇİ<sup>2</sup>, İ. Safa YILDIRIM<sup>1</sup>

SSK Ankara Hospital, Departments of Internal Medicine<sup>1</sup> and Radiology<sup>2</sup>, Ankara

*Hypereosinophilic syndrome is a spectrum of disorders characterized by marked eosinophilia of no identifiable cause and by organ dysfunction.*

*In 1999, a patient with marked weight loss, eosinophilia and a hypodense lesion in the right lobe of the liver was diagnosed as hypereosinophilic syndrome by fine needle aspiration biopsy and bone marrow aspiration biopsy. Echocardiography and thoracic HRCT was found to be normal.*

*The patient was prescribed 30 mg prednisolone daily with the dose being tapered gradually. At the end of treatment, computerized tomography was normal but ultrasonography showed a 1mm x 3mm lesion. Liver scintigraphy was then performed in order to determine the activity of the lesion and was found to be normal. The lesion was therefore thought to be from a previous infection.*

**Key words:** Hipereozinofilik sendrom, karaciğer, sintigrafi.

*Hipereozinofilik sendrom belirgin eozinofili ile karakterize, eozinofiliye neden olacak herhangi bir sebep tespit edilemeyen ve organ disfonksiyonuna neden olan bir hastalıktır.*

*1999 yılında belirgin kilo kaybı, eozinofilisi ve karaciğer sağ lobda hipodens lezyonu olan hastaya yapılan ince iğne aspirasyon biopsisi ve kemik iliği aspirasyon biopsisi ile hipereozinofilik sendrom tanısı kondu. Hastanın ekokardiografisi, toraks HRCT'si normal olarak bulundu.*

*Hastaya 30mg/gün dozunda prednisolon başlanarak doz tedrici olarak azaltıldı. Tedavi sonrasında bilgisayarlı tomografi normal olarak bulundu ancak ultrasonografide 1x3 mm boyutunda bir lezyon tespit edildi. Bu lezyonun aktivitesini tespit etmek için yapılan sintigrafi normal olarak bulundu. Ultrasonda tespit edilen lezyon sekel olarak kabul edildi.*

**Anahtar kelimeler:** Hypereosinophilic syndrome.

## INTRODUCTION

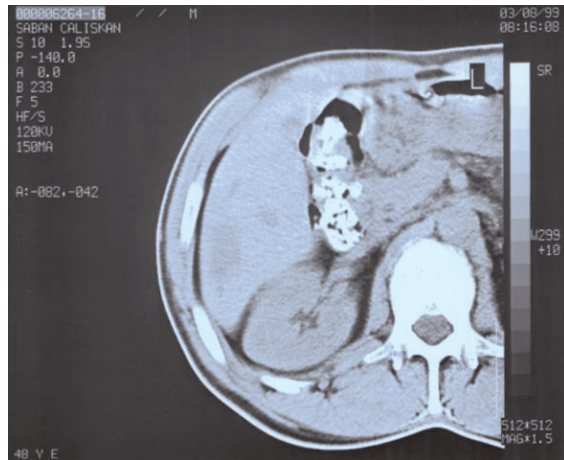
Hypereosinophilic syndrome (HES) is a spectrum of disorders characterized by marked eosinophilia with no identifiable cause or and by organ dysfunction (1). Criteria for the diagnosis include persistent eosinophilia of at least 1500 eosinophil/mm<sup>3</sup> for longer than six months, absence of parasitic, allergic or other known causes of eosinophilia and evidence of organ involvement (2).

This syndrome is mostly seen in males and is characterized by pulmonary, hematopoietic and central nervous system involvement.

## CASE REPORT

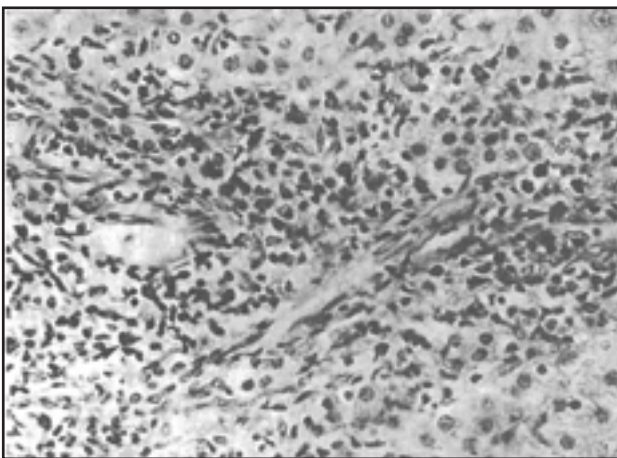
In August 1999, a 47 year-old male patient was admitted to the Social Security Hospital Internal Medicine Department with complaints of fatigue, fever, right upper quadrant abdominal pain and

weight loss. On physical examination, there was no lymphadenopathy but he had hepatomegaly of four cm, palpable under the right subcostal margin in the midclavicular line. On laboratory examination, WBC count was 13800/mm<sup>3</sup>, sedimentation was 80 mm/hr, AST was 47 U/L while coagulation parameters were within normal limits. In protein electrophoresis, the gammaglobulin level was found to be increased so Ig levels were evaluated and IgE was found to be more than 2000 IU/mL (increased). Peripheral blood smear was taken and 52% eosinophilia was found. Microscopic examination of stool for parasites was normal. Evaluation of hepatomegaly by abdominal USG showed an irregular bordered hypoechoic lesion 34mmx20 mm in size. In order to characterize the lesion abdominal CT was performed



**Figure 1.** Irregular bordered hypodense lesion was found by abdominal CT (size of 30x20 mms).

(Figure 1). The liver was found to be 19 cm in length and in the right lobe, a 3cm x 2cm irregular bordered hypodense lesion was found. By using a 3.5 mHz linear transducer, USG guided needle biopsy was taken from the hepatic lesion. The result of the biopsy was marked eosinophilic infiltration of the hepatic sinusoids and charcot leyden crystals, which is in keeping with HES (Figure 2). Bone marrow needle aspiration biopsy was taken and performed eosinophilic precursors were found to be increased. A provisional diagnosis of HES was made, echocardiography and thoracic HRCT performed and they all were found to be normal. On the basis of this diagnosis, 30 mg prednisolone daily was prescribed.

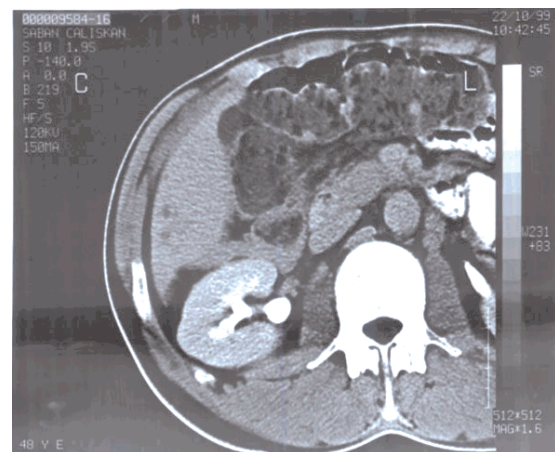


**Figure 2.** Liver biopsy of patient. The portal triad is enlarged, edematous and infiltrated with mononuclear cells and eosinophils.

The patient was followed up for 16 months, with 30 mg prednisolone being prescribed daily during the initial two months. At two month follow-up, the lesion was found to have decreased to 10 mmx6 mms in size at CT (Figure 3). Peripheral blood smear, complete blood count and sedimentation was also found to be normal. As a result of this improvement, steroid dosage was tapered to 20 mgs. Two months later, the lesion size was found to be 8mmx4 mm by USG. With monthly CBC, peripheral blood smear, liver function test and USG monitoring, prednisolone was tapered and stopped during the 12<sup>th</sup> month. At the last follow-up, CT was found to be normal, while abdominal USG identified a 1mmx3mm hypodense lesion. In order to determine the activity, scintigraphy was performed and found to be normal.

## DISCUSSION

Hypereosinophilic syndrome is a disease characterized by prolonged blood eosinophilia and organ dysfunction, probably caused by invasion of tissue by mature eosinophils (3,4). Men account for about 85% of patients and the syndrome primarily occurs in middle age (3,4). Patients commonly have involvement of hematopoietic, cardiovascular, hepatosplenic and pulmonary systems. Involvement of the nervous, lymphatic, GI and urinary system and skin is less frequent (5). Liver involvement occurs in 50-90% of patients with HES and is characterized by hepatomegaly and liver function test abnormalities (5-7). Liver involvement is reported in different series, In American series, hepatic involvement is found in



**Figure 3.** At two month follow-up, the lesion size was found to have decreased to 10mm x 6mm by CT.

32% of patients but it has not been reported in English series (8). Three patterns of liver involvement may be seen by USG: 1-multiple hypoechoic lesions, 2- one or two geographic hypoechoic lesions 3-diffuse hepatomegaly with granular paranchymal echogenity (6).

In our case, the lesion was single and hypoechoic. Hepatomegaly was detected on physical examination and CT but increase in the paranchymal echogenity was not reported at USG. Since a biopsy was not taken from liver paranchyma other than the lesion site, it is not known whether hepatomegaly had been caused by eosinophilic infiltration but marked to moderate hepatomegaly was reported previously. Croffy et al reported four cases without a lesion at USG but with hepatomegaly and where biopsy showed chronic active hepatitis (CAH) with eosinophilic infiltration (7). Also, Foongy et al reported a case with hepatomegaly and CAH who responded to steroid treatment (9). In our case, hepatomegaly decreased with treatment, which may indicate that the hepatomegaly was due to hepatic invasion by eosinophils.

In our case there was significant hepatomegaly and the lesion was seen by USG and CT to be infil-

trative in nature. Scintigraphy was not performed at the beginning of the treatment. The lesion size decreased with steroid treatment and all laboratory parameters returned to normal values. At the end of treatment, the lesion was not seen by CT but could be seen by USG and scintigraphy was therefore performed. White et al reported a case in which scintigram showed multiple focal defects in the liver but neither CT scan nor USG showed any abnormalities (9). These authors thought that abnormalities of Kupfer cells had led to the abnormal findings on scintigram. Shiomi et al also reported a case in which scintigrams showed multiple focal defects in the liver and CT scanning showed a low density lesion in the same area, but sonographic findings were negative (10). They suggested that the focal defect seen on scintigrams arose from a circulatory disturbance caused by easinophilic infiltration of the periportal area.

In conclusion, HES should be kept in mind in evaluation of focal lesions of the liver. Diagnostic tools include peripheral blood smear, bone marrow aspiration biopsy and fine needle liver biopsy. Corticosteroids have been shown to have great efficiacy in the treatment of HES.

## REFERENCES

1. Hardl WR, Anderson RE. Hypereosinophilic syndrome. *Ann Intern Med* 1968; 1220-9.
2. Chusid MI, Dole DC, West DC, et al. The hypereosinophilic syndrome. *Medicine* 1975; 54.
3. Epstein DM, Taormra V, Geftter WA, et al. Hypereosinophilic syndrome. *Radiolgy* 1981; 140: 59-62.
4. Kim B, Kwan JH, Long DS, et al. Hypereosinophilic syndrome; imaging findings in patients with hepatic involvement. *AJR* 1993; 161: 557-80.
5. Fauci AS, Barley JB, Robert WC, et al. The hypereosinophilic syndrome: clinical, pathophysiologic and theuropatic considerations. *Ann Intern Med* 1982; 97 : 78-92.
6. Nam KJ, Jung WJ, Choi JC, et al. Hepatic involvement in hypereosinophilia. *J Ultrasound Med* 1999; 18: 475-79.
7. Croffy YB, Kopelmen R, Kaplan M. Hypereosinophilic syndrome: assosiation with chronic active hepatitis. *Dig Dis Sci* 1988; 33: 233.
8. Weller P, Biple G. The Idiopathic hypereosinophilic syndrome. *Blood* 1994; 83: 2759-79.
9. While WL, Wagner HW, Brown ML, et al. Sequential liver imaging in hypereosinophilic syndrome: discordant images with scintigraphy, ultrasound and CT. *Clin Nucl Med* 1981; 675.
10. Shiomi S, Kuroki T, Veda T, et al. hypereosinophilic syndrome appearing as focal defect on liver scan. *Ann Nuclear Med* 1991; 5: 171.